



Module 1. Introduction to Stroke and Stroke Prevention

Objectives for Module 1

Knowledge

- Define the term “stroke” and distinguish ischemic from hemorrhagic stroke
- Compare and contrast ischemic stroke and transient ischemic attack (TIA)
- Describe 3 major mechanisms that can produce an ischemic stroke
- Name the most common causes of (1) non-traumatic subarachnoid hemorrhage and of (2) intraparenchymal (intracerebral) hemorrhage

Clinical Applications and Reasoning

- List at least 4 common symptoms of stroke that a layperson might report
- Explain why an individual who has recently had a myocardial infarction or has recently been diagnosed with atrial fibrillation is at increased risk for having a stroke
- Describe what would typically be seen in non-contrast CT scans showing the brain of a patient with acute intracranial hemorrhage
- Provide at least 2 reasons why immediate follow-up testing for a patient believed to have experienced a TIA is essential

Clinical Applications to Patient Education

- Develop 3 points that you would use in explaining what a stroke or a TIA is *to a patient*

Overview

A stroke is an episode of rapid-onset neurologic dysfunction resulting from injury to the brain, spinal cord or retina (CNS) that is caused by interruption of blood flow (ischemia) leading to focal infarction, or by bleeding into or around the brain (hemorrhage).

Permanent disabilities that are commonly associated with having a stroke include:

- Some weakness or paralysis on one side of the body
- Inability to walk without some assistance
- Cognitive impairment or dementia
- Difficulty in talking or in understanding what is being said
- Visual impairment
- Depressed mood
- Dependence on others to carry out activities of daily living (ADLs)

Stroke-related brain injury

A stroke can be triggered by one or a series of sudden vascular events that may last only a few minutes. The resulting damage to some brain cells initiates a cascade of chemical and cellular events injuring additional brain tissue that was not initially involved. In some strokes, it may be possible to abort these events and “rescue” much if not all of the brain. However, such a successful rescue requires medical or interventional therapies typically during the initial minutes and hours after the patient’s signs and symptoms first appear. Types of acute therapies and guidelines for their use have changed dramatically in the past 5 years, although much still remains to be learned. The brain continues to respond to its injury over a period that may last a few days or more, but at this later time the goal of therapy is preventing complications and further injury.

A stroke may kill the patient or produce permanent brain damage. If an individual survives a stroke, his or her specific long-term neurologic deficits will depend on many interacting factors including: the type and size of stroke, the specific parts of the brain that are involved, the effectiveness of any early medical treatment or interventions, continuing treatment and rehabilitation, and secondary prevention. Determinants of Health, including social, environmental, and economic factors like insurance status are all critical to an individual’s stroke risk and the aftermath of having a stroke.

STROKE FACTS – All data for the United States (reported 2021)

- About 795,000 people experience a new or recurrent stroke each year.
- All told, about 7.6 million adults ≥ 20 years old report having had a stroke.
- Epidemiologic data categorizing individuals on the basis of perceived race/ethnicity demonstrate that the age-adjusted incidence of ischemic stroke is significantly higher for Black than for White individuals. While stroke incidence has decreased overall in recent years, this racial/ethnic disparity has remained unchanged.
- Stroke is the fifth leading cause of death in the U.S., behind heart disease, cancer, unintentional injuries, and chronic lower respiratory diseases. Worldwide, stroke is the second most common cause of death after ischemic heart disease.
- The prevalence of stroke increases with age in both male and female individuals; however it is notable that 10% of all strokes occur in individuals 18 to 50 years of age.
- Each year more female than male individuals have a stroke and die of stroke.
- Stroke remains a leading cause of serious, long-term disability.
- The estimated direct and indirect cost of stroke in 2016-2017 was \$49.8 billion.

Based on American Heart Association 2021 Statistical Update

Death soon after a stroke is caused by brain-related or medical complications

The brain swelling (edema) that occurs after a stroke increases intracranial pressure. If there has been hemorrhage, the added volume of blood contributes to the increased pressure. The skull cannot expand. So when intracranial pressure (ICP) increases, “relief” can only be obtained by displacing brain tissue into a different compartment within the skull where the pressure is lower. This is referred to as brain “herniation.” If the forebrain is swollen, its displacement downward can produce compression of the brainstem. A stroke involving the brainstem itself (or the cerebellum) may also cause swelling and compression. If the reticular formation of the brainstem is involved, its dysfunction may result in irreversible coma, or in death because of respiratory arrest or circulatory failure. Measures to lower ICP and prevent herniation can include raising the head of the bed, IV mannitol, or surgical measures like removal of the skull overlying the swollen brain region.

Medical complications following a stroke can include pulmonary embolus due to deep venous thrombosis, pneumonia, or myocardial infarction to name just three. The recent decrease in the number of stroke deaths in the U.S. reflects improved acute stroke care and prevention of the medical complications of stroke. However improvement in the detection and treatment of hypertension beginning in the 1970s appears to have had the most substantial influence on the recent decline in stroke mortality.

Aggressive prevention can reduce a patient’s risk of having a first stroke

Individuals can decrease their risk of stroke and stroke mortality first and *foremost by controlling blood pressure*, as chronic hypertension is a powerful determinant of risk for both ischemic stroke and intracranial hemorrhage. Other important measures often associated with significant stroke risk reduction include abstaining from cigarette smoking, increasing physical activity, maintaining a BMI <25kg/m², managing blood lipid levels, and, if appropriate participating in treatment of diabetes mellitus, cardiovascular disease, and atrial fibrillation. Additional medical or surgical treatment can reduce the chances of strokes in individuals who are at particularly high risk, including those who have had a recent TIA (a warning sign of stroke) or myocardial infarction, or those with atrial fibrillation. Success in overall stroke risk reduction often involves addressing issues at both individual patient and health system levels.

Therapies administered during an acute ischemic stroke can sometimes reverse or limit brain injury

In certain patients, both thrombolytic and thrombus-extracting treatments may entirely reverse the course of an acute ischemic stroke or limit the permanent brain injury that it produces. However, their success requires recognizing that the patient is experiencing one or more warning signs of stroke, and acting immediately (by calling 9-1-1 or emergency medical services) so the patient reaches the hospital within the first 1-2 hours after symptoms began. The benefits of both therapies are time dependent, with earlier treatment associated with greater benefits. Studies suggest that at best only about one-third of those who have a stroke will access the ED in less than 2 hours.

Warning Signs/Symptoms of Stroke
<ul style="list-style-type: none">▪ Sudden NUMBNESS or WEAKNESS of face, arm or leg, especially on one side of body▪ Sudden CONFUSION, TROUBLE SPEAKING or understanding speech▪ Sudden TROUBLE SEEING in one or both eyes▪ Sudden TROUBLE WALKING, dizziness, loss of balance or coordination▪ Sudden, SEVERE HEADACHE with no known cause <p>(as described in patient education literature of the American Stroke Association)</p>

The American Stroke Association has adopted **F.A.S.T.** to help patients and witnesses easily remember the most common signs and symptoms of stroke and how they should respond:

- F** – Face Drooping
- A** – Arm Weakness
- S** – Speech Difficulty
- T** – Time to call 9-1-1 (emergency medical services)

Ongoing research should provide future physicians with additional ways to limit brain damage once the “triggering” vascular event has occurred, and to select the patients who are likely to benefit from these therapies. There are also exciting advances in the area of stroke rehabilitation.

At present, physicians are more successful at reducing the chances that a stroke will occur in the first place, than at reversing ongoing tissue injury or improving post-stroke function.

Strokes can be caused by either blockage or rupture of an artery

About 87% of strokes are ischemic – due to arterial occlusion. The resulting inadequate blood flow (ischemia) deprives the brain of oxygen and glucose, and slows the removal of metabolic wastes. The parts of the brain that the occluded artery can no longer adequately supply very rapidly begin to function abnormally or cease to function. If ischemia persists, brain cells die. The term “infarct” is commonly used to describe such a region of dead tissue. The brain is at special risk for ischemia because there is often not enough redundancy in its arterial supply to maintain adequate blood flow if one artery is suddenly occluded.

About 13% of strokes are hemorrhagic – due to arterial rupture. Bleeding can initially occur *within* the brain. Such intraparenchymal or intracerebral hemorrhages account for about 10% of strokes. Bleeding can also initially occur *around* the brain, in the subarachnoid space. Non-traumatic subarachnoid hemorrhage accounts for about 3% of strokes. A hemorrhage can produce injury by distorting, compressing, and tearing brain tissue (including its blood vessels), by the toxic effects of the blood itself, or by increasing intracranial pressure.

“Large” arteries and “small” arteries are both involved in stroke

The arteries that supply the central nervous system originate from the aorta or other great vessels. **“Large” arteries** are defined as the extracranial portions of the carotid and vertebral arteries and their large intracranial branches, which lie in the subarachnoid space *on the surface of the forebrain and brainstem*. These large arteries in turn give rise to “small” arteries.

“Small” arteries are the vessels that actually *enter brain tissue* and ultimately branch to form the capillary beds where oxygen exchange occurs. Some small arteries are short branches that supply superficial regions. However other small arteries are long branches that penetrate deep into the brain parenchyma to supply structures including the basal ganglia, internal capsule, thalamus, as well as parts of the brainstem and cerebellum.

Ischemic strokes most frequently involve narrowing or blockage of large arteries. Hemorrhagic strokes are more equally divided between the large and small arteries.

Strokes affect the forebrain most often, the brainstem or cerebellum less often, and the spinal cord rarely. This presumably reflects differences in the volume of tissue, and also in the sizes and arrangement of the arteries that supply these regions.

Introduction to Ischemic Stroke

In **StrokeSTOP** we will focus on ischemic strokes that occur if blood flow is blocked in an artery supplying the brain, producing focal ischemia. We will not discuss the severe widespread brain injury caused by failure of the entire circulation that affects all organs (systemic hypotension).

PREVIEW: The Three Major Types of Ischemic Stroke

1. Large Artery (arteries in neck or on brain surface)	Severe stenosis or occlusion caused by atherosclerotic thickening of wall. Often local thrombus formed on ulcerated atherosclerotic plaque may suddenly block the artery completely and trigger the ischemic event.
2. Small Artery (arteries that penetrate brain)	Occlusion may be by atherothrombosis, but more commonly lipohyalinosis in deeply penetrating small arteries (initiated by chronic hypertension) leads to the weakening and subsequent collapse of their walls occluding the lumen.
3. Embolic	Arterial occlusion (often at bifurcations or narrowed regions) caused by emboli from a cardiac source or from any of the large arteries supplying the brain, especially the carotid artery in the neck.

A little more about each major type of ischemic stroke:

1. Large Arteries can be occluded by atherosclerotic plaque, often accompanied by local thrombosis

Atherosclerosis often develops at the branch points or curving portions of both the extracranial and intracranial large arteries. These are locations where blood flow is slowed and more turbulent. The internal carotid artery is particularly at risk, although exactly where along its course the disease tends to occur and how quickly it progresses may reflect environmental, developmental and/or genetic factors, as well as the presence of additional risk factors that may stimulate plaque growth, such as hypertension and cigarette smoking.

Atherosclerosis involves focal accumulations of lipid, smooth muscle cells, foamy macrophages, and eventually cholesterol crystals, under the surface lining (endothelium) of the artery. With time these accumulations can form elevated plaques that protrude into the vessel's lumen and significantly reduce blood flow. Perhaps the analogy of a kitchen drainpipe becoming gradually plugged with cooking grease and sludge will help you visualize what is happening.

If occluding the vascular lumen weren't bad enough, plaques can do a number of additional things that further compromise the brain's circulation. For instance, a plaque can ulcerate (break open), and the resulting damage to its endothelial lining stimulates the development of thrombus (blood clot), which even further narrows the vessel. What's more, pieces of thrombus or plaque core can be swept along by the blood flowing through the vessel, becoming emboli (see Embolic stroke below)

A thrombus is a solid mass of platelets and/or fibrin (and other components of blood) that is formed locally in a vessel or the heart. Thrombi form when the clotting mechanism gets turned on. This is supposed to happen when you are injured. However, it can also occur at the site of an ulcerated atherosclerotic plaque, or whenever the endothelial cells that line the inner surface of an artery have been damaged. Thrombus formation may also occur in places where blood flow is sluggish, enabling clotting factors to activate and giving platelets more opportunity to stick together. Disorders of blood cells or blood proteins can increase the chance of thrombus formation, and therefore contribute to the risk of ischemic stroke.

2. Small Arteries can be occluded by pathology associated with hypertension, diabetes, and aging.

Blood flow in small arteries of the brain may be blocked by emboli or thrombus in the large arteries from which they branch. However, there are several additional kinds of pathology that uniquely affect the walls of small arteries, leading to their collapse and blockage of blood flow.

“Small” artery strokes preferentially involve *long penetrating* arteries and arterioles that supply deep central forebrain structures including the basal ganglia, internal capsule, thalamus, and deep cerebral white matter, as well as central regions of the pons and cerebellum. These slender penetrating vessels may be particularly affected by **hypertension** because many of them branch directly from large high-flow, high-pressure arteries at nearly right angles and in addition have thin muscular walls. Sustained high blood pressure is believed to initiate a degenerative process called **lipohyalinosis**, in which the walls of affected small vessels become stuffed with glassy “hyaline” material consisting largely of lipoproteins. This can eventually lead to weakening of the wall and progressive occlusion of the lumen.

A second different process that can also occlude small vessels is the formation of **microatheroma**, which is basically the same atherosclerotic process that affects larger caliber extra and intracranial vessels. Commonly microatheroma formation, like lipohyalinosis, affects the long penetrating vessels, although microatheroma may also affect short superficial vessels supplying the cortical surface. Patients with hypertension and diabetes appear to be especially susceptible to the formation of microatheroma in small brain arteries.

Elderly individuals in particular may have strokes due to narrowing or occlusion of short arteries and arterioles supplying the cerebral cortex caused by **amyloid angiopathy**. The underlying pathology does not seem to be associated with high blood pressure or diabetes, but rather is caused by accumulation of beta amyloid protein in vessel walls, progressively weakening them and eventually leading to severe luminal narrowing or occlusion. Beta amyloid is also one the major abnormal proteins present in Alzheimer’s disease, and amyloid angiopathy may add superficial cortical ischemic strokes to the already-devastating degenerative effects of Alzheimer’s disease.

Occlusion of small arteries supplying brain structures causes **small-vessel strokes**. These are also called **lacunar strokes** because the area that is infarcted takes the form of a small lacune or cavity (usually less than 15mm in diameter). Although the area infarcted by a small vessel stroke may be small, it can lead to major neurologic deficits. A much larger infarct may actually produce a less extensive (or intrusive) neurologic deficit for the patient. This is because the deficits after stroke depend on exactly what structures are involved.

3. Emboli carried by the bloodstream can occlude both large and small arteries

An embolus is most often a piece of a thrombus that has broken free and is carried toward the brain by the bloodstream. You’ll often encounter the term **thromboembolus** because it turns out that most emboli arise from thrombi, although bits of plaque, fat, air bubbles, and other material also qualify as emboli. Presumably an embolus floats along with the flowing blood until it encounters a narrowing in the artery through which it cannot pass (for instance a bifurcation or a region of elevated plaque). When the embolus gets stuck it blocks the artery, reducing blood flow to downstream tissues and thus rendering them ischemic.

Two Key Sources of Emboli to the Brain

- **Cardiac:** Cardiac disease is the most common cause of cerebral embolism. Atrial fibrillation leads to blood pooling in the left atrium or atrial appendage and therefore increased thrombus formation. Thrombus can also form on damaged or prosthetic mitral or aortic valves, or in the left ventricle if the pumping action of the heart is suboptimal because of a myocardial infarction. Fragments of these thrombi can enter the systemic circulation and travel to any organ, including the brain.
- **Arteries Supplying the Brain -- Artery-to-Artery Embolism:** Ulcerated atherosclerotic plaque at the carotid bifurcation or nearby regions of the internal carotid artery is the most common source of artery-to-artery emboli. Bits of thrombus that have formed on the damaged endothelium or fragments of the plaque core itself can break off and then be carried distally in the carotid circulation to reach the brain or retina. Atherosclerosis can potentially develop in any of the extra- or intracranial parts of large arteries supplying the brain, providing additional sources of emboli.

The diameters and branching patterns of the large arteries have a lot to do with where embolic material tends to travel, and where it tends to ultimately lodge. For instance, the large diameter, gently curving course, and rapid blood flow in the middle cerebral artery put it at particular risk for embolism – and therefore the regions of brain that it supplies at risk for embolic stroke. The smaller anterior cerebral artery, which originates from the internal carotid at a sharper angle, captures emboli less often – emboli apparently don't corner well!

Ischemic strokes may be preceded by Transient Ischemic Attacks (TIAs)

A TIA is a brief episode in which neurological deficits suddenly occur and then disappear, caused by focal brain, spinal cord, or retinal ischemia. Most of these events last only a few minutes to an hour or so, although the classic definition includes events that persist up to 24 hours before they fade. Unlike a stroke, the neurologic exam demonstrates no remaining functional deficits once the TIA has ended. However while their clinical symptoms may have resolved, we now know that as many as one-third of patients who experience a TIA will have new (acute) infarctions (regions of cell death in the CNS attributable to ischemia) visualized by diffusion-weighted magnetic resonance imaging (MRI).

Some strokes occur “out of the blue” but a number of ischemic strokes are preceded by one or more TIAs. Sometimes the symptoms produced by recurrent TIAs are exactly the same each time they occur. Other times the symptoms are different, and can even occur on the other side of the body. Remember that a TIA occurs when an artery is temporarily blocked. If the same region of one artery is being blocked each time, this would produce the same symptoms. How would you explain TIAs that produce different symptoms? (*Answer: a different region of the same artery or another artery altogether is being blocked.*)

A TIA is an important warning sign of stroke. A TIA is an important warning sign that the stage is set for an ischemic stroke, because it demonstrates that enough vascular and/or cardiac pathology is present to produce neurologic symptoms. *You could think of a TIA as the brain practicing having a stroke!* Patients with possible TIAs require urgent evaluation, determination of stroke risk, and initiation of appropriate stroke prevention therapy. Treatments that specifically target these underlying disorders and risk factors can significantly reduce the chances that patients who have experienced TIAs will later have a stroke (permanent neurological deficits). We will discuss some of them in later modules.

TIA FACTS – Data for the United States (2021)

- About 12% of all strokes are preceded by a TIA, based on retrospective patient reports.
- Many patients who experience TIA-like symptoms fail to inform their healthcare providers.
- The incidence of TIA increases with age. TIAs are more frequent in male than in female individuals. Epidemiologic data organized by perceived race/ethnicity indicate higher rates of TIAs in Black than in non-Hispanic White people.
- Short-term risk of stroke and other vascular events following a TIA has historically been reported as high as 5% at 2 days, and as high as 11% at 90 days. However more recent studies report lower rates, perhaps reflecting better and faster evaluation of acute TIA and implementation of secondary stroke prevention strategies in the study populations.

The term ‘**mini-stroke**’ is sometimes used in describing a TIA to emphasize the severity of the event and the importance of obtaining immediate medical attention, even though the episode of impaired neurological function may last only a few minutes. The risk of a stroke that produces lasting neurologic deficits in the hours or days following a TIA is substantial, but may be significantly reduced when it is treated on an urgent basis.

During a Transient Ischemic Attack an artery is *temporarily* blocked.

One mechanism explaining what happens during a TIA is embolization of platelet aggregates, small thrombi or plaque debris from the extracranial vessels supplying the brain or from the diseased heart. This material travels into a brain or retinal artery and briefly plugs it up, reducing blood flow to a specific downstream region and causing its dysfunction. However if the embolic material quickly fragments and passes distally, then circulation through that part of the artery is re-established and normal function returns. Since little if any tissue has actually died, the patient has no permanent neurologic deficit. A second mechanism sometimes proposed to explain TIAs is a low perfusion state, usually thought to result from carotid artery stenosis. However this would require a large drop in blood pressure and is now thought to be a less common mechanism of TIA.

There is really no such thing as a transient *hemorrhagic* attack. It would be very unusual for hemorrhage *into brain tissue* to cause transient, focal neurological deficits because the signs/symptoms can be reversed only when the blood has been removed -- a process that takes weeks or even months, not minutes. Major hemorrhages *into the subarachnoid space* caused by aneurysm rupture are sometimes preceded by a warning leak, more formally called a sentinel bleed. Again, this does not usually produce transient focal (specific) deficits, but rather a headache that lasts several days. (See the next section for more about Hemorrhagic Strokes)

If patients don't tell you about symptoms consistent with a TIA, or if you fail to recognize that they could be describing a TIA, you will miss an opportunity to intervene and perhaps prevent a major stroke!

Introduction to Hemorrhagic Stroke

Intraparenchymal (also called Intracerebral) Hemorrhage is bleeding directly into the brain and ventricles. This is the most common type of intracranial hemorrhage. **Hypertensive intraparenchymal hemorrhage** is usually caused by spontaneous rupture of a small penetrating artery deep in the brain. The most common sites are the basal ganglia (especially the putamen), internal capsule and deep white matter of hemisphere, thalamus, and central regions of the pons and cerebellum). As discussed when we talked about ischemic strokes, the small arteries supplying these regions are particularly susceptible to chronic untreated hypertension, which apparently initiates lipohyalinosis. This pathology weakens the walls of small penetrating arteries and arterioles. Classic teaching links lipohyalinosis to the formation of microaneurysms (called Charcot-Bouchard aneurysms) that may subsequently rupture.

In the extremely elderly, the walls of small “short” arteries and arterioles supplying the *superficial* regions of the cerebral hemispheres may develop deposits of amyloid protein (**cerebral amyloid angiopathy**), also discussed with small-vessel ischemic stroke. These weakened vessels can rupture causing hemorrhages in the superficial regions of the hemispheres. The resultant hemorrhages are referred to as **lobar hemorrhages**, presumably because they involve outer portions of the various lobes of the brain. Recall that they often occur in elderly individuals who have had normal blood pressure throughout their lives, and appear to be more closely associated with the presence of Alzheimer’s disease than with hypertension.

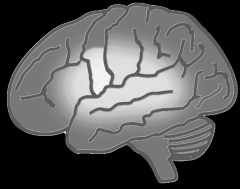Non-traumatic **subarachnoid hemorrhage** (bleeding around the brain) is most commonly caused by rupture of **saccular (berry) aneurysms**. These aneurysms are thought to be a consequence of a developmental abnormality. They get their name because they typically include a protruding neck and a thin-walled dome. The aneurysms commonly form at the branch points of large or medium-sized intracranial arteries in or near the Circle of Willis, and most often involve arteries of the anterior (carotid) circulation. Aneurysms rupture into the subarachnoid space, usually in the basal cisterns, but hemorrhage may extend secondarily into the adjacent brain tissue as well. Aneurysms usually announce their presence only when they rupture. Less often, they may reveal themselves by compressing neighboring structures and producing neurologic symptoms. Occasionally aneurysms may bleed just a little prior to a more massive rupture. A warning like a sudden unexplained headache or other neurological disturbance may make it possible to identify the problem, and to initiate surgical or endovascular intervention if it is indicated.

The neurologic deficits produced by hemorrhagic strokes can reflect damage to regions of the brain *remote* from the affected artery. There are several reasons for this: (1) When an artery ruptures, blood under arterial pressure is forcefully shot into the brain and can travel a long distance (2) Increased intracranial pressure due to the sudden addition of hemorrhaging blood can compress and distort brain tissue located at some distance from the site of arterial rupture.

What CT scans can show about ischemic and hemorrhagic stroke

A Head CT (Computed Tomography) scan *without contrast* is usually the first radiologic test ordered when a patient presents with neurologic symptoms suggesting a stroke or TIA.

When there is acute hemorrhage into the brain, the accumulated hemoglobin makes the area look bright (hyperdense) in CT images. Very early ischemic strokes are NOT detected on routine CT scans. A non-contrast head CT scan in the first hours of symptom onset is used to *exclude* hemorrhagic stroke, not to confirm ischemic stroke. Contrast material is not used, because the normal presence of hyperdense contrast material in blood vessels and meninges could mask a small hemorrhage. Identifying the cause of stroke is essential if the administration of thrombolytic drugs is being considered to restore cerebral perfusion. Diffusion-weighted imaging (DWI) is far more sensitive for directly visualizing very early ischemic infarction than is either CT or standard MRI.



Module 2. Stroke Risk Factors Preventing Strokes

Objectives for Module 2

Knowledge

- Name at least 6 important risk factors for stroke
- Briefly relate each risk factor you named to stroke pathogenesis, based on current knowledge

Clinical Applications and Reasoning

- Develop a series of questions that would enable you to screen a patient for major stroke risk factors, and create a stroke risk profile for that individual
- Discuss at least 4 ways that structural and/or social determinants of health could influence a patient's stroke risk profile.
- Propose 2 different ways that individuals living in a community might be encouraged to learn more about stroke, and to take part in a screening for stroke risk factors
- Suggest at least 1 health policy or legislative initiative to increase primary stroke prevention programs for all U.S. residents, and address current stroke-risk factor disparities

Clinical Applications to Patient Education

- Develop 3 points that you would use in explaining *to a patient or family member* how their hypertension is related to stroke risk, and what preventive measures you recommend.

Risk factors reflect the pathology that is responsible for the major types of strokes. Many risk factors have some role in *promoting or accelerating atherosclerotic plaque formation and ulceration*. This makes sense when you remember that 87% of all strokes are ischemic, and that atherosclerosis plays an important role in the majority of ischemic strokes.

Flow-limiting stenosis of major extracranial or intracranial vessels caused by plaque may produce ischemia. However, it is usually thrombotic material that acutely occludes large or small intracranial vessels and is the immediate cause of ischemia. Also recall that a thrombus that threatens blood flow to the brain can form locally in a cerebral vessel itself, or it can form in more distant sites including the aortic arch, arteries in the neck, or the heart and then detach and travel as an embolus to reach the brain.

Other important stroke risk factors therefore include conditions that *promote formation of thrombi in these more distant locations*. *Hypertension is the most significant of the stroke risk factors*. It is linked not only to atherosclerosis but also to lipohyalinosis (a major contributor to small-vessel ischemic strokes). Hypertension is also the major cause of intraparenchymal hemorrhage.

Some of the risk factors for stroke can be treated or controlled. In most cases, there is good evidence that treatment leads to significant reductions in the occurrence of stroke and in death from stroke. It has been estimated that if current prevention activities were uniformly performed at levels achieved by the best U.S. health care delivery systems, approximately 20% of strokes would be prevented (*Circulation*. 2008; 118:576; also see module 6). **Successful preventive measures often require addressing that patient's social and economic as well as biomedical issues.** For example, a patient who is unable to obtain fresh produce and other healthy food will be unable to follow medical advice to "eat a healthy diet." A patient whose neighborhood is unsafe may be unable to "take daily walks" in order to increase physical activity.

KEY MEDICAL & BEHAVIORAL STROKE RISK FACTORS

High Blood Pressure	Smoking/Tobacco Use
Diabetes Mellitus	Physical Inactivity
Atrial Fibrillation	Nutrition (Poor diet patterns)
Myocardial Infarction	Obesity (key component of Metabolic Syndrome)
High Blood Cholesterol (and other lipids)	Excessive Alcohol Consumption (includes binge drinking)

Chronic Kidney Disease, Sleep Apnea, Short Sleep Duration, Depression, Chronic Stress

ADDITIONAL FACTORS SHOWN TO INCREASE STROKE RISK

Age	The risk of having a stroke, and short-term risk of death after a stroke both increase with age.
Sex	Males have more strokes than females up to the age of 65, but at older ages the difference narrows. Females tend to have greater disability after stroke than males, likely because they are on average older at stroke onset. The peripartum and postpartum periods are associated with increased risk. At this time there is no consistent evidence that current oral contraceptives or gender-affirming hormone therapies by themselves affect stroke risk.
*Family History Ethnicity Ancestry Genetics	Stroke is a highly complex disease, comprising a group of heterogeneous disorders in which multiple genetic and epigenetic factors interact with environmental risk factors. Twin studies support a role for genetic factors in stroke pathogenesis, and an individual’s risk may be increased if a first-degree relative has had a stroke. Possible mechanisms may include: genetic heritability of risk factors or susceptibility to their effects; shared environmental factors; interaction of genetic and environmental factors. These components are increasingly being identified and evaluated by genome-wide association studies.
Previous Stroke or TIA	These are the most significant stroke risk factors, since both indicate the presence of significant vascular pathology. TIAs and stroke confer substantial risk both in the short and longer term.

* We did not use the term “race” in this table because its definition is variable and often context dependent.. However perceived race continues to be cited in many epidemiologic studies.

KEY POINT: Biomedical factors, Health Systems structure, Health Care policy/processes, and Social Determinants of Health ALL contribute directly or indirectly to an individual’s burden of Stroke Risk Factors and their ability to achieve or maintain health. Multiple interrelated considerations include biologic, social, environmental, economic factors, insurance status, availability of screening programs, exposure to racism and discrimination

Combination of Risk Factors for Stroke. Each risk factor that is listed is associated with an increase in stroke risk, but to varying degrees. Although an increase in the number of risk factors corresponds directly with a further increase in stroke risk, the relationship is not linear.

More About Factors That Increase Stroke Risk

High Blood Pressure (HBP)

High blood pressure has previously been defined for research purposes as SBP ≥ 140 mm Hg or DBP ≥ 90 mm Hg, taking antihypertensive medications, or being told at least twice one has HBP. However, recent **ACC/AHA Guidelines recommend that HBP be defined as $\geq 130/\geq 80$. HBP is the single most important modifiable risk factor for both ischemic and hemorrhagic stroke.**

STROKE RISK: Using the recent lower threshold, nearly one-half of all US adults have **high blood pressure. This at least doubles their lifetime risk of stroke, independent of other risk factors.** Long-term control of high blood pressure at target levels significantly reduces stroke risk. Recent trials suggest that intense systolic BP control (to <120 mm Hg) may have further benefit.

Although we don't yet understand the relative contributions of biomedical, structural and social determinants of health, bias and racism, multiple epidemiologic studies have shown that overall adult Black Americans of African ancestry tend to develop high systolic blood pressure relatively early in life, and this in turn is likely associated with a high number of first-ever ischemic strokes.



Relationship to stroke pathogenesis: Atherosclerotic plaque development in extracranial or intracranial arteries supplying the brain is a slowly progressive process that apparently begins in the teenage years. Arteries that are continuously subjected to high pressures are more likely to develop plaque, and it is also more likely that the endothelial surface of the vessel will be damaged, promoting plaque rupture and the formation of thrombi. A thrombus can occlude the vessel locally or can break off and potentially embolize the brain. Hypertension likely initiates lipohyalinosis of small arteries that deeply penetrate the brain, which makes their walls prone to rupture (producing an intraparenchymal brain hemorrhage) or to collapse, occluding the lumen and producing a small ischemic infarct.

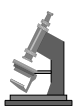
A little about control/treatment: An ongoing U.S. study shows continuing increases in awareness and treatment of HBP over the past 10 years. However only approximately 25% of those being treated for HBP have their blood pressure consistently controlled.

For a small number of patients, treatment of kidney, adrenal or thyroid disease can reverse hypertension. However for most patients, the cause of hypertension is not known. Most blood pressure management plans combine risk factor modifications like more fruits/vegetables and lower fat in diet, weight loss, increased physical activity, alcohol moderation, smoking cessation, and often one or more medications. Adherence to such a plan is difficult for many patients—but now imagine the additional challenges posed by social and structural factors like low income level, unemployment, food insecurity, housing/neighborhood conditions, limited health literacy, lack of community-based health services, or the constant stress of structural racism. Lowering stroke risk for ALL individuals will require mitigating these issues and building additional support structures.

BOTTOM LINE: Recent meta-analyses indicate that systolic blood pressure <130 mmHg may be the most clinically advantageous blood pressure target in the prevention of stroke.

Myocardial Infarction

STROKE RISK: At more than 45 years of age, approximately 4% of males and 7% of females who have a first myocardial infarction (MI) will go on to have a stroke within 5 years. The risk of stroke is far greatest in the first months following an MI because of the increased risk of an embolic event.



Relationship to stroke pathogenesis: Since atherosclerosis is the underlying pathology for both MI and most ischemic strokes, this relationship should not be a surprise. Furthermore, an MI may produce damage to the heart wall or persistent atrial fibrillation, both of which promote thrombus formation. Bits of thrombus may break off and embolize the brain.

Finally, the thrombolytic agents used to treat an MI by breaking up clot in the coronary vessels increase the risk of intracerebral hemorrhagic strokes.

A little about control/treatment: **Since many of the risk factors for stroke and MI are the same, preventing a second MI or a stroke will involve many of the same considerations.** These may include changes such as smoking cessation, increasing fruits/vegetables and reducing fat in the diet, moderation of alcohol consumption, and increasing physical activity. Medical therapies may include reducing blood pressure, antiplatelet agents, anticoagulation if cardiac problems that increase the risk of thrombus formation are present, statins or other lipid-lowering agents, and medical treatment of diabetes mellitus if it is present. Again, consider the effects of social and economic determinants, biases and inequalities on a patient's ability to carry out these recommendations.

Atrial Fibrillation (AF)

Atrial fibrillation is the most common cardiac dysrhythmia. Estimates of its prevalence in the U.S. ranged from about 2.7 to 6.1 million in 2010. Being white and older both increase the risk of AF.

STROKE RISK: AF is a powerful risk factor for ischemic stroke, independently increasing risk about 5 times, regardless of age. It is also an independent risk factor for stroke severity, recurrence, and mortality. The percentage of stroke attributable to atrial fibrillation increases from 1.5% at 50-59 years of age to 23.5% in *Seniors* aged 80-89. (NOTE: These numbers may be significant underestimates, as atrial fibrillation is often asymptomatic and may not be detected clinically.)



Relationship to stroke pathogenesis: Patients with atrial fibrillation have a greatly increased risk of embolic strokes. Ineffective contraction of the atrium allows blood to pool along its walls encouraging thrombus formation. Bits of these thrombi can travel through the left ventricle, enter the systemic circulation and embolize the brain.

A little about control/treatment: In some patients, atrial fibrillation resolves spontaneously. Cardioversion, ablation, or drug therapy may be used to restore a normal cardiac rhythm. However none of these approaches has been shown to reduce short-term stroke risk. By contrast, in patients with chronic nonvalvular atrial fibrillation, anticoagulation with warfarin significantly reduces stroke risk compared with untreated patients, but it requires monitoring. For patients who have a low overall stroke risk or for whom warfarin therapy is not an option, an antiplatelet agent like aspirin or clopidogrel may be considered. Anticoagulants that do not require monitoring are now available (e.g. dabagatran or apixaban) and may replace warfarin in some cases. Clinical decisions about use of these therapies must consider the risk of hemorrhagic complications.

Diabetes Mellitus

In DM the body is unable to produce or respond properly to insulin. DM is defined as a fasting plasma glucose ≥ 126 mg/dL or HbA1c $\geq 6.5\%$. It is estimated that more than 10% of the adult U.S. population has diagnosed or undiagnosed diabetes.

STROKE RISK: Ischemic stroke incidence is increased 2-6 fold in patients diagnosed with type 1 or type 2 diabetes mellitus compared to patients with normal glucose levels. *Even when glucose levels are considered "well controlled," diabetes is associated with a 1-3 fold increased the risk of stroke in adults.* Identifying and treating diabetic patients will significantly reduce their risk of many other vascular complications of diabetes. However, since diabetes puts these patients at high risk for stroke, it is particularly important to control any of their additional risk factors for stroke, such as blood pressure. In diabetic hypertensive individuals, aggressive treatment of hypertension has been associated with significant reduction in stroke risk.



Relationship to stroke pathogenesis: Diabetes increases the risk of ischemic strokes through several interrelated mechanisms that favor (and accelerate) the formation of atherosclerotic plaque. In patients with diabetes, plaque is much more common in the smaller branches of cerebral arteries than in non-diabetic individuals. The narrowing of these smaller vessels can directly increase the risk of stroke.

High Blood Cholesterol and Other Lipids

STROKE RISK: No *consistent* association has been demonstrated between levels of total cholesterol, HDL-C (good) cholesterol, or LDL-C (bad) cholesterol with overall stroke risk (all types combined). Although you will often read that high total cholesterol is a major risk factor for ischemic stroke, the data are actually conflicting. In contrast, the data associating levels of total cholesterol and other serum lipids with atherosclerotic cardiovascular disease are far more robust.

Further research is needed on any associations with ischemic stroke, specific ischemic stroke subtypes, or hemorrhagic stroke.



Relationship to pathogenesis: Concerning *cerebrovascular* disease specifically, what is known is that elevated total cholesterol and LDL-C is associated with increased degree and progression of carotid atherosclerosis, while elevated HDL-C levels have the opposite effect.

A little about control/treatment: To reduce the risk of myocardial infarction (and possibly stroke), recommended levels for adults are total cholesterol <200 mg/dL and HDL-C \geq 40 mg/dL. An individual's LDL-C goal depends on how many additional risk factors they may have. The recommended levels may be achieved by diet, increased physical activity, and/or cholesterol-lowering agents (statins or other pharmacological agents).

Note that the statins (3-hydroxy-3-methylglutaryl coenzyme A reductase inhibitors) may have important effects on atherosclerotic disease in addition to their lipid-lowering properties, and recent studies show that they reduce stroke risk.

Carotid Artery Stenosis

STROKE RISK: Narrowing of the carotid artery can be symptomatic, producing a stroke or transient ischemic attack (TIA), or asymptomatic. This depends on factors like whether the plaque surface is disrupted, increasing the likelihood of thrombus formation (a thrombus can directly block the artery or be a source of emboli) or whether there is an effective collateral circulation that supplements the blood supply to brain regions in the jurisdiction of the partially occluded carotid.



Relationship to stroke pathogenesis: When a carotid artery is narrowed by atherosclerotic plaque so that the cross-sectional area of its lumen is reduced by 70% or more, the patient has a significantly increased risk of stroke.

A little about control/treatment: When a carotid artery is narrowed \geq 70%, carotid endarterectomy (surgical removal of fatty deposits) is often considered. This procedure has been shown to significantly reduce stroke risk for both symptomatic and asymptomatic patients, but has associated surgical risk. Early intervention after the onset of symptoms is now often recommended. More recently, minimally invasive angioplasty with or without stenting has become available. The results of clinical trials comparing long-term outcomes and considering factors such as patient age and sex continue at this time. Blockages \leq 30% are often treated using lipid-lowering agents (statins) and antiplatelet therapy, with the combined goals of slowing atherosclerotic disease and reducing the risk of thrombus formation.

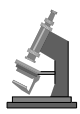Smoking/Tobacco Use

In 2016, about 15% of the U.S. population age 18 years and over were currently cigarette smokers.

STROKE RISK: Current smoking increases the risk of stroke 2-4 times in both males and females, compared to nonsmokers or former smokers who have quit for >10 years. Specifically, cigarette smoking has been shown to be an independent risk factor for both ischemic stroke and subarachnoid hemorrhage). Exposure to secondhand smoke during adulthood also increases stroke risk about 30%. Discontinuation of smoking reduces stroke risk across sex, race, and age groups. When an

individual quits smoking, stroke risk begins decreasing almost immediately, and after 10 years drops to nearly that of a nonsmoker. The health risks of e-cigarettes continue to be studied.

Smoking may impact the effect of other stroke risk factors on stroke risk. For example, Cigarette smoking increases the stroke risk of individuals with high blood pressure, and smokers with elevated systolic blood pressure who also use oral contraception have increased stroke risk.



Relationship to stroke pathogenesis: Cigarette smoke contains carbon monoxide and nicotine as well as numerous additional toxic compounds. Cigarette smoking has a role in promoting the atherosclerotic process particularly in the carotid arteries. (It is thought that carbon monoxide may play a role in damaging the arterial endothelium). In addition, it also causes microvascular damage. Smoking also causes several changes in the blood. They include increased adhesiveness and clustering of platelets, shortened platelet survival, faster clotting time, and increased viscosity of the blood, which can affect flow velocity. Many of these same changes in the blood can also be caused by short exposures to secondhand smoke; their effects are not known.

Physical Inactivity

Higher levels of physical activity are associated with lower stroke risk across all racial/ethnic groups, ages, and in both males and females. ≥ 150 minutes of moderate aerobic exercise or ≥ 75 minutes of vigorous exercise weekly (together with strength training) is associated with lower risk of both ischemic and hemorrhagic stroke. Physical activity improves stroke risk factors as it helps control obesity and diabetes, increases levels of HDL cholesterol, and may lower blood pressure in some people. Currently, about 24% of U.S. adults self-report meeting physical activity guidelines.

Excessive Alcohol Consumption

STROKE RISK: The incidence of ischemic stroke in those who consume *small* amounts of alcohol (an average of 1-2 drinks per day for males and 1 for females) is *lower* than in nondrinkers. The reasons may involve a reduction in coronary artery disease. However, chronically drinking too much alcohol (≥ 5 drinks per day) and/or acute binge drinking are significant risk factors for stroke.



Relationship to stroke pathogenesis: The exact pathogenic mechanism is unknown, but alcohol can contribute to high levels of triglycerides, produce cardiac arrhythmias, and cause heart failure.

A little about control/treatment: In the case of alcohol abuse, counseling and support groups.

Obesity

STROKE RISK: Obesity, defined as a body mass index (BMI) of 30.0 kg/m^2 or greater, increases the risk of ischemic stroke relative to individuals with a lower BMI. In 2015-16, about 38% of U.S. adults were obese. Abdominal body fat is an independent risk factor for ischemic stroke in all race/ethnic groups. In many cases obesity predisposes individuals to other stroke risk factors including diabetes, hypertension, and atrial fibrillation.

Nutrition

STROKE RISK: Adherence to a Mediterranean-type diet rich in nuts and olive oil, a diet that includes fish, fruits and vegetables, oatmeal and rye bread, or a diet rich in fruits and vegetables is associated with a reduced risk of stroke. Conversely, consumption of sugar-sweetened or artificially sweetened diet soda, and a higher salt intake have each been associated with a greater risk of stroke.

The proportion of adults with a “healthy diet” (as defined by the American Heart Association) has increased overall during the past 10 years. However the increase is significantly smaller for those living with chronic poverty. *Food insecurity is associated with obesity, hypertension and diabetes, which then places people at greater risk for stroke.*

Populations and Individuals at Special Risk for Stroke

A Few Introductory Thoughts and Examples

We are only at the beginning in understanding health related biological traits that may track to some extent with what is called “race” or “race/ethnicity”, and other traits that instead reflect the consequences of living as a member of a particular race/ethnic group in the United States. **Both the quality of national and local U.S. healthcare systems/processes and social determinants of health, including any experiences of bias, racial discrimination and health care disparities, have major impacts on both stroke prevention and stroke outcomes, as well as overall health.**

We have selected several populations at special risk for stroke to briefly discuss. As you read about them, we urge you to consider various factors that might contribute directly or indirectly to an increased incidence of stroke and adverse health outcomes – and how those conditions might be addressed at the individual, community, and population levels.

Non-Hispanic Black individuals living in the United States

PREFACE: How closely or poorly do drivers of stroke risk (the underlying causes of stroke) correspond with racial groupings? One example to consider: Epidemiologic studies of stroke in the U.S. have generally grouped individuals whose ancestors hail from the different regions of Africa in a single “Black” or “African American” race/ethnicity category. However there is actually greater genetic diversity within this racial category than between black and white races.

Epidemiologic studies categorizing individuals based on race/ethnicity consistently report that the annual incidence for first-ever stroke is significantly higher for black individuals than white individuals for ischemic infarcts, intracerebral hemorrhage and subarachnoid hemorrhage. Between 45 and 64 years of age, both black males and females have a particularly high stroke/TIA risk. **A number of investigators now suggest that the roots of this racial disparity are likely to be environmental exposures and social processes (determinants of health).**

Of the stroke risk factors we previously discussed, level of systolic blood pressure appears to account for about half of the increased risk among black compared to white individuals. **Aggressive preventive measures in recent years are credited with decreasing average blood pressure levels in both black and white populations. However, the racial disparity in the prevalence of high blood pressure and in the incidence of stroke remains unchanged.**

In this example we focused on Black-White racial disparities in stroke incidence and/or mortality in the U.S. because they have been identified and studied since the 1950s. However, racial/ethnic disparities in stroke incidence and/or mortality are also reported in other U.S. populations including Hispanic or Latino, and American Indian/Native Alaskan.

QUESTION: What are several national and/or local approaches you would suggest to reduce these Black/White (and other) disparities in stroke incidence in the U.S.?

The Stroke Belt: A Geographic Region in the U.S. Whose Residents Have Unexplained High Stroke Mortality

Rates of stroke mortality are highest in a region of the southeastern US which is known as the ‘Stroke Belt.’ This area is variably defined, but usually includes the states of North Carolina, South Carolina, Georgia, Tennessee, Mississippi, Alabama, Louisiana, and Arkansas. In this region average stroke mortality is about 30% higher than in the rest of the US. This geographic disparity has existed more or less unchanged for the past 70 years. Even more striking, within this ‘Stroke Belt’ the coastal regions of North Carolina, South Carolina, and Georgia have average stroke mortality that is about 40% higher than in the rest of the nation.

Black individuals who live in this so-called ‘Stroke Belt’ have sharply increased stroke mortality rates; mortality rates for whites are also increased, but remain significantly lower than for black individuals. The high rate of stroke among ‘Stroke Belt’ residents does not appear to be the result of poor hypertension treatment and control. Recent analyses show that stroke incidence is highest for residents who were born in the stroke belt and lived there for the first 20 years of their lives. A clear explanation for the existence of the Stroke Belt has so far eluded public health experts.

QUESTION: Do you have thoughts about factors that could contribute to creating a “Stroke Belt”? The experts seem to be baffled, so feel free to make suggestions and think outside the box.:

Older Adults

Individuals >85 years of age comprise about 17% of all stroke patients. Atrial fibrillation becomes increasingly common with age, and this may contribute to the increased incidence of stroke. Amyloid angiopathy (and the lobar hemorrhages that are associated with this small vessel pathology) is also most common in the elderly. However, the major risk factors for stroke do not change with age. Accumulation and destabilization of atherosclerotic plaques with accompanying thrombus formation remains the pathology underlying the majority of strokes. If anything, **the influence of structural and social determinants on stroke prevention becomes at least as significant with age.**

A final point: despite the fact that strokes in older adults are more severe and are associated with high one-month mortality, treatments for stroke are still beneficial. Evidence supports offering intravenous tPA, mechanical thrombectomy and carotid endarterectomy to elderly stroke patients who meet treatment guidelines.

QUESTIONS: What strategies might physicians, other health care professionals and health systems use to help SENIORS lower their stroke risk at both an individual and community level?

Sickle Cell Disease

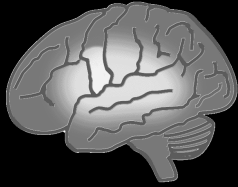Sickle cell disease is defined as homozygosity for the sickle cell mutation in the beta-globin gene. Among other things, the abnormal hemoglobin causes repeated episodes of erythrocyte “sickling.” This damages the vascular endothelium and makes it prone to thrombus formation. Individuals, especially children, with sickle cell disease are at high risk of stroke as well ischemic damage resulting in severe pain or multisystem organ damage.

Sickle cell disease is prevalent throughout large areas of sub-Saharan Africa, the Mediterranean basin, the Middle East and India where heterozygosity for the sickle cell mutation (sickle cell trait) provides strong protection against malaria. An estimated 100,000 individuals in the U.S. currently have the disease.

The severity of sickle cell disease varies, apparently depending on both genetic modifiers (for instance, factors that control the expression of fetal hemoglobin) and non-genetic modifiers including cold exposure, air quality, infection control, and availability of screening programs. **Even in this most common inherited monogenic disorder the structural and social determinants of health play key roles in disease expression as well as in the patient’s quality of life.**

POTENTIAL RACE-BASED DIAGNOSTIC BIAS: There is a common misconception that sickle cell disease affects only Black people. In fact, **sickle cell disease is associated with populations at risk for malaria NOT with race.** Relying on a false racial association as a diagnostic criterion could mean missing the opportunity for early diagnosis and preventive interventions like use of transcranial Doppler screening and regular blood transfusions.

QUESTION: What are several downstream negative effects of race-based diagnostic bias?



Module 3. The Blood Supply of the Brain Relating Vascular and Functional Anatomy

Objectives for Module 3

Knowledge

- Describe or sketch the course of the major arteries and their branches that comprise the carotid and vertebral-basilar systems.
- Name the major arteries or branches whose territories include the following structures:
 - Lateral parts of the hemisphere and large regions of internal capsule and basal ganglia (deep structures)
 - Anterior Medial and Superior parts of hemisphere including anterior corpus callosum
 - Posterior Medial and Inferior parts of the hemisphere including posterior corpus callosum
 - Thalamus
 - Medial brainstem
 - Lateral brainstem and Cerebellum
- Name the major arteries (and branches) that supply: Primary motor cortex for face, arm, leg; and corticobulbar and corticospinal fibers in deep white matter of hemisphere, and throughout the rest of their course in the forebrain and brainstem.
- Name the major arteries that supply the different components of the visual system, regions involved in language processing/production, spatial attention and visual-spatial orientation.
- List 4 important regions where collateral circulation may provide alternate routes for blood flow to the brain.

Clinical Applications and Reasoning

- Explain why collateral circulation may not protect against brain ischemia when a major artery is abruptly occluded.
- Explain why a slowly developing occlusion of the internal carotid artery in the neck might be totally asymptomatic.
- Name at least 3 structures where both intraparenchymal hemorrhages and small-vessel (lacunar) infarcts are common, and suggest an anatomic feature shared by their blood vessels.

It may be helpful to look at the relevant StrokeSTOP reference drawings as you read this module

The brain derives its arterial supply from the paired **carotid** and **vertebral** arteries. Every minute, about 600-700 ml of blood flows through the carotid arteries and their branches, while about 100-200 ml flows through the vertebral-basilar system.

The carotid and vertebral arteries begin extracranially, and course through the neck and base of the skull to reach the cranial cavity. The internal carotid arteries and their branches supply the anterior 2/3 of the cerebral hemispheres, including many deeper as well as superficial structures.

The vertebral arteries and basilar artery, with their branches, supply the remaining posterior and medial regions of the hemispheres, most of the diencephalon, the brainstem, cerebellum, and cervical spinal cord. The carotid and vertebral-basilar circulations are anatomically interconnected with each other, and with their counterparts in the opposite hemisphere, through the circle of Willis. However these connections may not be functionally significant if the connecting vessels are of small diameter or if pressure differences are too small to drive much blood flow.

The Carotid Circulation

Overview of Major Regions Supplied:

- optic nerves and retina
- cortex and deep white matter of the frontal and parietal lobes, and lateral aspects of the temporal and occipital lobes
- all of the corpus callosum except its posterior regions
- most of the basal ganglia and internal capsule.

Course of the Carotid Arteries and Formation of Major Branches

The right common carotid artery originates from the bifurcation of the brachiocephalic trunk, while the left common carotid artery originates directly from the aortic arch. Each common carotid then branches to form the internal and external carotid arteries. After the internal carotid artery ascends through the neck, traverses the temporal bone, and passes through the cavernous sinus it pierces the dura and finally reaches the subarachnoid space at the base of the brain.

Just after it enters the subarachnoid space the internal carotid artery usually gives rise to its first intracranial branch, the **ophthalmic artery**, which travels along the optic nerve into the orbit. There its branches supply the retina and other structures of the eyeball itself, as well as other structures in and around the orbit. The internal carotid artery continues in a superior direction and usually gives off two additional branches: the **posterior communicating** and **anterior choroidal** arteries.

The posterior communicating artery usually links the internal carotid to the posterior cerebral artery, and may be large or threadlike. However, in some individuals one or both of the posterior cerebral arteries retain their embryological state as direct branches of the internal carotid artery itself. The anterior choroidal artery is a small artery that supplies mainly deep structures. It usually branches from the internal carotid, but it may also branch from the middle cerebral artery. For this reason, we will discuss it with the middle cerebral artery. Finally, the internal carotid artery divides to form the **anterior and middle cerebral arteries**.

Anterior Cerebral Artery

The **anterior cerebral artery (ACA)** arises from the internal carotid at nearly a right angle. It sends deep penetrating branches (called lenticulostriate arteries) to supply the most anterior portions of the basal ganglia. It then sweeps forward into the interhemispheric fissure, and then runs up and over the genu of the corpus callosum before turning backwards along the corpus callosum. As it runs backwards it forms one branch that stays immediately adjacent to the corpus callosum while a second branch runs in the cingulate sulcus (just superior to the cingulate gyrus) To summarize, **ACA** supplies the medial and superior parts of the frontal lobe, and of the anterior parietal lobe.

ACA usually supplies these Key Functional Areas:

- septal area and anterior cingulate gyrus (limbic system -related cortex)
- anterior medial frontal lobe (complex roles in behavior and judgment)
- primary motor cortex for the leg and foot areas, and the medial frontal micturition center
- primary somatosensory cortex for the leg and foot
- most of the corpus callosum except its posterior part. Among other things, these callosal fibers enable the language-dominant hemisphere to find out what the other hemisphere is doing, and to direct its activities.

The short **anterior communicating artery** joins the two anterior cerebral arteries. It may provide collateral flow to the opposite hemisphere if the carotid artery is occluded on either side.

Middle Cerebral Artery

The **middle cerebral artery (MCA)** has a large diameter and branches at an acute angle from the internal carotid. The MCA passes laterally just underneath the frontal lobe, ultimately taking up a position between the temporal and frontal lobes in the lateral (Sylvian) fissure. The initial part of the MCA is a single vessel --its stem or M1 segment. As it passes laterally, the stem gives off a series of 6-12 long, small diameter, penetrating arteries that travel directly upward through brain tissue to supply large regions of the basal ganglia and internal capsule. These are the **MCA lenticulostriate arteries**.

Clinical Note: The lenticulostriate arteries are small diameter arteries that originate as right angle branches from the MCA stem (a large diameter vessel with a brisk, high pressure blood flow). These small penetrating arteries are particularly susceptible to damage caused by lipohyalinosis, pathologic changes weakening their walls that are associated with prolonged hypertension. They may either rupture, producing an intracerebral hemorrhage that is initially centered in the region they supply, or they may collapse, blocking the lumen and producing a small (lacunar) ischemic infarct in the tissue they normally supply. The lenticulostriate arteries are 'end arteries' and regions that they supply do not have significant collateral blood supply. Therefore their occlusion leads to stereotyped stroke syndromes.

Clinical Note: In the case of the lenticulostriate arteries, hemorrhage may remain localized to the putamen, caudate or internal capsule, affect other more distant white matter of the hemisphere, or even rupture into the ventricular system. Small-vessel (lacunar) infarcts may have serious functional consequences if they involve motor or sensory fibers in the internal capsule but may be 'silent' (produce no functional deficit) if they involve other small regions of white matter or the basal ganglia.

In addition to these lenticulostriate arteries, small penetrating **anterior choroidal artery** branches also supply deep structures including parts of the globus pallidus and putamen, and thalamus, as well as posterior regions of the internal capsule. Recall that the posterior limb of the internal capsule contains the corticospinal and corticobulbar motor tracts and connections between the somatosensory thalamus and cortex. Thus infarcts in either lenticulostriate or anterior choroidal territory can cause contralateral hemiparesis and hemianesthesia.

Once in the lateral fissure itself, the MCA stem divides into two or, in a smaller number of cases, three main cortical branches that supply almost the entire lateral surface of the brain as well as the insula.

Clinical Note: Large emboli carried up the carotid tend to be swept into the MCA stem, but may then get stuck at its narrower branch point within the lateral fissure, reducing blood flow to its major cortical branches. An embolus in the MCA stem could also block one or more small penetrating (lenticulostriate) arteries at their origin from the stem.

The **superior** (upper or suprasylvian) **cortical MCA branch** gives rise to several arteries that supply much of the lateral and inferior frontal lobe and often the anterior lateral parts of the parietal lobe. The **inferior** (lower or infrasyllvian) **cortical MCA branch** gives rise to arteries that supply the lateral temporal lobe including its anterior tip, variable amounts of the lateral parietal lobe, and much of the lateral occipital lobe. Note that details of the territories supplied by the superior and inferior cortical branches vary in different individuals.

Clinical Note: Emboli can lodge in one of these two major cortical branches, as well as in the smaller arteries that each of them will subsequently form.

Superior cortical branches of MCA usually supply these Key Functional Areas:

- Primary motor cortex for face and arm, and *axons* originating in the leg as well as face and arm areas that are traveling in the deep white matter toward the internal capsule as part of the corticobulbar or corticospinal tracts
- Broca's area and other related gray and white matter important for language expression -- in the language-dominant (usually L) hemisphere
- Frontal eye fields (important for 'looking at' eye movements to the opposite side)
- Primary somatosensory cortex for face and arm (But be aware that this cortex and even the primary motor cortex can be supplied by inferior branches in some people)
- Parts of lateral frontal and parietal lobes important for lateralized attention (perceptions of one's own body and of the outside world), visuospatial analysis, and for expressing emotions with the voice and body language -- in the R hemisphere

Inferior cortical branches of MCA usually supply these Key Functional Areas:

- Wernicke's and other related areas important for language comprehension in the language- dominant (usually L) hemisphere
- Parts of the lateral parietal and temporal lobe important for lateralized attention, and visuospatial analysis, and for the ability to interpret emotions in the voices and body language of others -- in the R hemisphere
- primary somatosensory cortex, and sometimes also part of the primary motor cortex
- Optic radiations. Axons that carry information about the contralateral superior quadrants of the visual fields loop forward into the temporal lobe (they are located anterior and lateral to the temporal horn of the lateral ventricle). Recall that the optic radiations traveling deep in the parietal lobe carry information from the contralateral inferior quadrants.

Clinical Note: There is a tendency for atheromatous plaques to form at branch points and curves of the cerebral arteries. Thus in the carotid circulation frequent sites of plaque formation include the extracranial internal carotid artery at its origin from the common carotid, in the stem (M1) MCA or its bifurcation into superior and inferior divisions, or in the ACA as it curves backwards over the corpus callosum.

Vertebral-Basilar Circulation

Overview of Major Regions Supplied

- upper cervical spinal cord
- brainstem and cerebellum
- most but not all of the thalamus and hypothalamus
- cortex and deep white matter of the posterior medial parietal lobes, and medial and inferior temporal and occipital lobes (including the posterior hippocampus)
- posterior part of the corpus callosum (splenium)

The **vertebral arteries** usually arise from the subclavian arteries. They ascend through the upper cervical transverse foramina, turn medially along the upper surface of the atlas, pierce the dura to enter the subarachnoid space and ascend into the cranial cavity via the foramen magnum. The vertebral arteries run alongside the medulla, giving rise to branches that participate in supplying the cervical spinal cord as well as the brainstem. They end by fusing to form the basilar artery.

Clinical Note: Cardiac emboli tend to enter the vertebral circulation far less frequently than the carotid circulation. Several facts of vascular anatomy may account for this. Each vertebral artery takes off from the subclavian at a sharp angle, and has a much smaller diameter. By contrast, the internal carotid artery is about the same diameter as the common carotid, and makes only a slight bend at its origin. Also, the vertebral-basilar system handles only about 20% of the total cerebral blood flow, while the carotid system handles far more.

The vertebral arteries help to supply the cervical spinal cord. The posterior spinal arteries and the two anterior spinal arteries, which fuse to form a single midline vessel, supply the upper cervical cord. Blood that supplies more caudal regions of the spinal cord flows to it via radicular arteries that are branches of the thoracic and abdominal aorta. There is a great deal of variability in this pattern. The artery of Adamkiewicz is one of the most important radicular arteries, and in some individuals it may provide the entire arterial supply for the lower two-thirds of the cord.

The vertebral and basilar arteries supply the brainstem and cerebellum. Perhaps the most important thing to recognize about the brainstem's blood supply is just how variable the arteries can be in size and position, but still provide adequate perfusion. This means that clinical syndromes produced by occlusion of a particular artery are also variable. Patients you will encounter may present with fragments or combinations of "classic" brainstem syndromes.

Brainstem arteries in the medulla, pons and midbrain have similar patterns of distribution:

- **Medial parts of the brainstem** as far dorsal as the ventricle are supplied by long, slender **paramedian penetrating arteries**

Clinical Note: Like the lenticulostriate branches of MCA, these paramedian arteries are at risk for hypertensive damage, particularly in the pons. Large hemorrhages in the ventral medial pons classically damage the corticospinal (and corticobulbar) tracts and other medial structures bilaterally. Occlusion of these paramedian vessels in the pons can produce small (lacunar) infarcts that may infarct these same structures.

- **Dorsolateral parts of the brainstem** are supplied by **short circumferential penetrating branches of the vertebral or basilar arteries**, or by branches of one of the major 'cerebellar' arteries as they curve around the brainstem to reach the cerebellum (**penetrators from long circumferential arteries** (primarily AICA or PICA). The midbrain is also partially supplied by posterior cerebral artery branches.

The blood supply of the medulla is derived from the two vertebral arteries. The midline **anterior spinal artery**, formed from the fusion of medial branches from each vertebral, supplies part of the central medulla (as well as much of the upper cervical cord). From its lateral side each vertebral gives off a variable branch the **posterior inferior cerebellar artery (PICA)**. PICA has a complicated looping course as it swings out around the inferior olives, and runs along the dorsal lateral surface of the medulla before turning laterally and supplying the inferior surface of the cerebellum. The vertebral arteries fuse at the junction between the medulla and the pons to form the single midline **basilar artery**, which then proceeds rostral along the surface of the anterior pons. The basilar artery also gives rise to additional large lateral arteries, most importantly, the **anterior inferior cerebellar arteries (AICA)** and the **superior cerebellar arteries**.

The three pairs of named cerebellar arteries supply the posterior inferior, anterior inferior, and superior surfaces of the cerebellum respectively. The superior cerebellar artery also sends small branches penetrating deeply into the internal (deep) nuclei of the cerebellum.

Clinical Note: Less commonly, these penetrating superior cerebellar artery branches are also at risk for hypertensive hemorrhage, with bleeding often occurring deep within the cerebellum. Such a cerebellar hemorrhage can produce deficits related to the cerebellum such as postural instability or limb ataxia. It may also affect the brainstem by compression or by rupture into the fourth ventricle. This can kill the patient by interrupting vital respiratory and cardiac functions

Vertebral-basilar branches supply the following key functional areas:

Brainstem Region	Medial Structures	Dorsolateral Structures
Rostral Midbrain	*CST and CBT in cerebral peduncle Superior cerebellar peduncle Oculomotor nucleus / CNIII axons Medial longitudinal fasciculus Rostral Reticular formation	
Mid-Pons	Medial longitudinal fasciculus Reticular formation CST and CBT Griseum pontis	Middle cerebellar peduncle Trigeminal sensory and motor nuclei / axons Spinothalamic tract
Caudal Pons	Abducens nucleus/CNVI axons Motor fibers of CNVII PPRF (lateral gaze center) CST and CBT Medial lemniscus Caudal Reticular formation	Facial motor nucleus/CNVII axons Middle cerebellar peduncle Descending tract/nucleus of V Spinothalamic tract Vestibular and Cochlear nuclei CN VIII axons
Rostral medulla	Hypoglossal nucleus/CNXII axons CST Medial lemniscus Caudal Reticular formation	Nucleus ambiguus/CNIX and CNX axons Descending tract/nucleus of V Spinothalamic tract Vestibular nuclei Inferior cerebellar peduncle

*CST = corticospinal tract; CBT = corticobulbar tract

Clinical Note: If an embolus travels in one vertebral artery, its passage may be blocked where the vertebral arteries join to form the basilar artery. More often, however, it keeps going, traversing the basilar artery (which has a large diameter) but is arrested at the upper bifurcation of the basilar into the posterior cerebral arteries or in one posterior cerebral artery (PCA)..

As each PCA passes around the cerebral peduncles, it forms short penetrating branches to the **midbrain**, and gives rise to a series of long, slender penetrating arteries that supply much of the **hypothalamus and thalamus**. The circle of Willis partially surrounds the hypothalamus, and additional small perforators from its other arteries also help to supply the hypothalamus.

Clinical Note: After the basal ganglia and internal capsule, the thalamus is the next most frequent site of hypertensive intracerebral hemorrhage and small-vessel infarcts. Thalamic hemorrhages may be confined to the thalamus, or the bleeding may involve the neighboring internal capsule, subthalamic nucleus and midbrain, and even rupture into the third ventricle.

The **cortical branches of PCA** supply the posterior medial parietal lobe and the splenium of the corpus callosum, inferior and medial part of the temporal lobe including the hippocampus and entorhinal cortex (medial temporal lobe), and the medial and inferior surfaces of the occipital lobe.

Penetrating branches of PCA usually supply these Key Functional Areas:

DIENCEPHALON including the thalamus, subthalamic nucleus, and hypothalamus

MIDBRAIN including the cerebral peduncle, third nerve and nucleus, superior cerebellar peduncle, and reticular formation

Note: The upper parts of the Basilar artery also help supply the midbrain

Cortical branches of PCA usually supply these Key Functional Areas

PARIETAL AND OCCIPITAL LOBE (Posterior branches)

- Optic radiations and striate cortex (the primary visual cortex may be entirely supplied by PCA, or the tip of the occipital lobe where the fovea is mapped may be located in the border zone shared by PCA and MCA)
- Splenium of the corpus callosum (these crossing fibers participate in the transfer of visual information to the language-dominant hemisphere)

MEDIAL TEMPORAL LOBE (Anterior branches)

- Posterior hippocampus, entorhinal cortex and the fornix (these structures are critical for laying down new declarative memories)

Clinical Note: Recall that atherosclerotic plaque forms at branch points or curves in vessels. In the vertebral-basilar circulation, it is most frequent in the cervical part of the vertebral arteries and where the vertebral arteries join to form the basilar artery. Plaques are also common in the PCA as it swings around the midbrain on its way to medial parts of the parietal, occipital, and temporal lobes.

Overall cerebral blood flow is constant, but can vary locally

Although we've discussed anatomic variations of the cerebral arteries, our description up to now suggests that they are a system of rigid branching pipes. In reality, however, the cerebral vessels continuously adjust their own caliber by contraction and relaxation of smooth muscle in their walls so that:

- constant cerebral blood flow is normally maintained over mean arterial pressures ranging between approximately 60-150 mm Hg. Thus as intra-arterial pressure goes up, cerebral vessels normally constrict and conversely when pressure drops, the cerebral vessels dilate. However, at extremely low or high arterial pressure levels this response fails, and in those situations cerebral blood flow follows blood pressure more directly. The concept that cerebral vessels themselves have a role in controlling cerebral blood flow is often referred to as **autoregulation**.
- local blood flow can change in response to local neuronal metabolism. For example, increases in arterial (and hence extracellular) carbon dioxide tension in a specific brain region will lead to dilation of its arterioles and an immediate increase in local blood flow.

These responses protect the brain from ischemia by increasing cerebral blood flow (delivery of oxygen and glucose, and removal of carbon dioxide and other metabolites) in the face of decreased arterial pressures. They also support regional variations in brain activity by providing rapid local adjustments of blood flow.

Collateral circulation may modify the effects of cerebral ischemia

There is usually not enough redundancy in the blood vessels of the brain to support function if one artery is suddenly occluded. If there were, ischemic strokes would be far less frequent.

Many smaller penetrating brain arteries such as the lenticulostriate branches of MCA that supply the basal ganglia and internal capsule, as well as the penetrating branches from arteries on the brain surface that supply deep white matter, are **terminal arteries**. This means that they form few if any connections with other arteries. When they are occluded, the brain regions they supply will therefore become ischemic.

Other arteries form anastomoses that potentially could protect the brain from infarction, or at least limit the amount of damage, by providing alternative routes for blood flow.

Common and Important Anastomoses can occur between:

- External carotid and internal carotid via branches of the ophthalmic artery
- The major intracranial arteries via the circle of Willis (for example one carotid might supply parts of the contralateral hemisphere by connections through the anterior cerebral and anterior communicating arteries)
- Muscular branches of cervical arteries and the extracranial vertebral or external carotid arteries
- Small cortical branches of ACA, MCA, and PCA, or branches of the major cerebellar arteries

How effective the collateral circulation can be in supporting blood flow and hence neurologic function depends on the size of the arteries. The smaller the diameter of the collaterals, the less likely it is that they will be able to carry enough blood to prevent infarction.

The speed at which the occlusion of an artery occurs therefore can play a role in determining whether collateral circulation will be sufficient to prevent infarction.

If a major artery is gradually occluded by atherosclerosis, there may be time for preexisting collateral channels to enlarge to the point where they can support major blood flow. This may happen, for instance, when there is gradual occlusion of the internal carotid artery in the neck by the build up of atherosclerotic plaque. In this situation retrograde flow may develop *from* the external carotid through the ophthalmic artery *to* the intracranial internal carotid, bypassing the blockage. Some people with one or both internal carotid arteries largely or entirely occluded show no neurologic deficits thanks to collateral circulation around the orbit.

The ‘circle’ of Willis can be a source of effective collateral circulation. At first glance, the anatomy of the circle of Willis suggests that blood can be easily shunted from one side of the brain to the other, or from the carotid to the vertebral-basilar system or vice versa. This may indeed occur, especially in younger individuals. However if one or more of the arteries that forms the circle is narrowed, then the circular connections might not allow enough blood flow to compensate for most *abrupt* arterial blockages. In this case, it would provide little ‘protection’ against sudden blockage of a vessel by, for example, a cardiac embolus. In the same patient, the circle might be able to compensate for slowly developing arterial occlusions produced by build-up of atherosclerotic plaque, since even if arteries of the circle are initially small diameter they may expand over time in response to increasing hemodynamic demands.

Before we leave the circle of Willis, we should point out that places where large arteries branch or bifurcate are favorite locations for the formation of **saccular (‘berry’) aneurysms**. In these locations the muscular part of the arterial wall is relatively weak, and balloon-like swellings that are prone to rupture may occur. The greatest number of aneurysms involve the anterior portion of the circle of Willis: the junction of the anterior communicating artery with ACA, the junction of the internal carotid and posterior communicating artery, or the division of MCA into superior and inferior branches within the lateral (Sylvian) fissure. If an aneurysm ruptures, blood under high pressure is forced into the subarachnoid space, which contains the circle of Willis, and possibly into the interior of neighboring brain substance as well. Such non-traumatic subarachnoid hemorrhages account for about 3% of all strokes.

Concept of Border zone versus core territory of the cerebral vessels

We have seen that the cerebral cortex is supplied by the cortical branches of MCA, ACA, and PCA. These arteries reach the cortical surface, divide, and give off branches that penetrate the cortex perpendicularly. Long arteries and arterioles pass through the gray matter and penetrate the white matter to a depth of 3-4 cm, where they supply the core of the hemisphere’s white matter. These arteries intercommunicate very little, and thus constitute many independent small systems. The deeply penetrating vessels that branch directly from major arterial stems (like the lenticulostriate branches of MCA) also do not interconnect. Therefore if one of these arteries is occluded, the “downstream” tissue it normally supplies will be infarcted since it has no other source of blood flow.

By contrast, the short surface arteries supplying the cortical gray matter do anastomose. The anastomoses form a continuous network of tiny arteries covering the perimeters or **border zones** between the core (central) territories of the 3 major cerebral arteries. Since these anastomoses are usually tiny, they carry little blood. Therefore, if one of the major arteries is occluded, the anastomoses cannot rescue the core territory of that artery from infarction. However, they may be able to supply the border zone, so that the size of the infarction is reduced somewhat. Additional contributions of leptomeningeal collaterals connecting the ACA, MCA and PCA along surface of the brain may also serve to limit ischemia. Conversely, if there is a dramatic impairment of systemic blood pressure (perhaps secondary to cardiac arrest or massive bleeding), or decreased pressure specifically in the carotid system (due to an occlusive event), the border zones, which are the regions of each vascular territory farthest from the core will become ischemic first.

ACA – MCA Border Zone may include these Key Functional Areas:

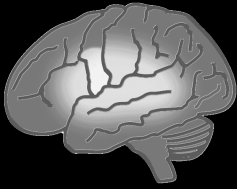
- Hip, shoulder or less usually arm region of primary motor or somatosensory cortex
- Areas related to language production – in the dominant hemisphere
- Frontal eye fields
- Frontal lobe motor planning areas

ACA/MCA – PCA Border Zone may include these Key Functional Areas:

- Visual radiations
- Foveal region of the striate cortex in some people (in others it may be in PCA territory)
- Inferior temporal lobe cortex (the fusiform gyrus) important for visual recognition
- Areas related to language comprehension, word finding, and possibly reading –in the dominant (usually left) hemisphere
- Areas of parietal lobe important for lateralized attention and visuospatial perceptions – in the right hemisphere

Infarction or hemorrhage caused by problems in the venous rather than the arterial system is fairly rare. Venous thrombosis is associated with medical conditions that lead to a prothrombotic state, and also with blood volume depletion, medications, or head trauma. Its frequency increases in women during pregnancy particularly in the third trimester, and in the first 6 weeks postpartum. Usually large sinuses (e.g. the superior sagittal sinus) and large veins are most affected. Said simply, what often happens is that blockage of a large vein can ‘back up’ the circulation in a region, causing decreased arterial flow that in turn produces ischemia and infarction (and sometimes hemorrhage into the infarcted tissue).

Clinical findings in these patients usually do not reflect the typical arterial territory syndromes that you have been learning about. One of the reasons for this may be that there are far more functional anastomoses in the venous than in the arterial system. While problems secondary to occlusion of cerebral veins may not be particularly helpful in learning about the territories supplied by the cerebral arteries, they are very important to consider from a clinical perspective. They are rare, accounting for only about 1% of all strokes, but they are treatable if identified early on.



Module 4. Ischemia in Carotid Territory Introduction and Key Clinical Examples

Objectives for Module 4

Knowledge

- Describe two common clinical presentations of TIAs caused by ischemia in carotid territory.
- Describe at least one mechanism that may explain transient monocular visual loss.
- List 4 of the major signs and symptoms seen after occlusion of the MCA stem in the language-dominant and in the non-dominant hemisphere, and relate each of them to damage in a specific neuroanatomic structure.

Clinical Applications and Reasoning

- Explain how occlusion of the internal carotid artery in the neck (extracranial) can produce several different patterns of neurologic deficits (or in some cases, none at all).
- Compare and contrast the patterns of clinical findings seen after occlusion of the *superior* MCA division in the language-dominant (usually left) vs the non-dominant hemisphere.
- Compare and contrast the patterns of clinical findings seen after occlusion of the *inferior* MCA division in the language-dominant vs the non-dominant hemisphere.

Clinical Applications to Patient Education

- Develop points that you could use in explaining to a patient how he or she might personally experience a TIA produced by temporary occlusion of carotid branches.

Carotid territory includes the retina and much of the anterior and lateral cerebral hemisphere. Key clinical problems referable to ischemia in carotid territory can be produced by occlusion of either the *extracranial* internal carotid artery (ICA) or its major *intracranial branches*, including the ophthalmic artery, middle cerebral artery (MCA) or anterior cerebral artery (ACA).

TIAs involving the carotid artery or its branches

Transient monocular visual loss

Case Summary

The patient was sitting watching television when his vision suddenly went “blurry and cloudy” for about 3-4 minutes and then returned to its usual state over the next 10 minutes. He wasn’t convinced that anything had really happened, but then later on that evening he had another episode. This time he tried checking one eye at a time, and discovered that his right eye was fine, but that the vision in his left eye was “blurry.” He called 911 because he remembered seeing something about this kind of problem on a Brain Attack poster in his doctor’s waiting room.

Expert Note: Work-up suggested that this patient has experienced two episodes of transient monocular visual loss (*amaurosis fugax*) that has an ischemic cause—TIAs. Many patients describe a blackout, a cloud or a “gray fog” that obscures vision in one eye, or in part of one eye. Occasionally it is likened to “a shade falling over the eye.” Usually the attacks are very brief, lasting about 1- 5 minutes, and are followed by full restoration of vision, as this patient

experienced. The patient is at risk of hemispheric stroke, permanent visual loss, or myocardial infarction.

Two general mechanisms are proposed to explain this type of TIA. (1) A tiny piece of thrombus formed on an ulcerated plaque at or near the carotid bifurcation, or a piece of the underlying plaque itself breaks off, enters the ophthalmic artery, and lodges in a retinal arteriole. Ophthalmoscopic observation of the retinal vessels during actual episodes of transient monocular blindness has shown bits of whitish material (small emboli) temporarily blocking the retinal arteries. (2) A low perfusion state resulting from ICA stenosis (and probably temporary formation of thrombus that further blocks the vessel) causes regions far from the site of stenosis (like the retina) to become briefly ischemic.

There can be a number of different reasons for a transient loss of vision in one eye, such as inflammation of the arteries that supply the eye. However, in older patients the cause is more likely carotid occlusive disease produced by significant atherosclerosis and plaque erosion in the extracranial ICA. The patient was evaluated for stroke risk factors and preventive measures were recommended (see module 2).

Transient hemispheric attacks

Case Summary

This 73-year-old female noticed that her left arm suddenly went “limp.” This lasted about 20 minutes and then things were fine. She drove herself to the emergency room where they thought she might be having a heart attack. When cardiac testing showed no problems, she was sent home. The next day she noticed “numbness” in two fingers of her left hand that lasted a bit longer but resolved completely. The third day she again experienced numbness in the same two fingers and called her primary care physician, who arranged an urgent neurology consult. The patient was admitted to the hospital. Later that day she developed additional deficits involving her face, her enunciation of words (“I lisped”), and left arm strength. Auscultation of her neck revealed a right carotid bruit (noise from turbulent blood flow that can be caused by vessel narrowing). Right carotid stenosis, greater than 70%, was confirmed by ultrasound and cerebral arteriography. It was also found that she had developed significant external to internal carotid blood flow through anastomoses of these vessels around her right eye. She was treated surgically (a carotid endarterectomy), and is now taking antihypertensive medications, a statin agent, and a daily aspirin. Three years later, she has experienced no further neurologic problems.

Expert Note: This patient had not one but a series of TIAs initially involving the arm and hand area of the motor and perhaps somatosensory cortex, both supplied by carotid branches. TIAs in carotid artery territory typically produce varying combinations of:

- one-sided limb weakness or clumsiness
- one-sided numbness, paresthesias (abnormal sensations like burning) or loss of sensation
- Some problem with language (production or comprehension) – if L hemisphere involved
- Some problem articulating words, often described as ‘slurring’ words (dysarthria) Note that this is “lispings” as she called it is NOT aphasia, which is a problem with language.
- Partial or complete homonymous visual field defects (less commonly noticed by patients)

Stroke work-up demonstrated a well-established collateral circulation involving her ophthalmic artery, suggesting that carotid stenosis had been steadily progressing over a period of time. She underwent carotid endarterectomy (surgical removal of accumulated plaque). This has been shown to decrease stroke risk in patients with high-grade carotid stenosis (70-99%) In individuals 70 years of age or younger, carotid artery angioplasty with stenting appears an acceptable alternative. Long-term data regarding the outcomes of stenting continue to be collected, but current study data suggest that clinical outcomes for endarterectomy and stenting are similar in patients like this.

Common Strokes involving the carotid artery or its branches

We will consider the following five Stroke Syndromes produced by occlusion of the internal carotid artery and its branches because they are the most common and therefore the most important to understand.

Blocked Artery or Branch	PATTERNS OF POSSIBLE DEFICITS
Extracranial Internal Carotid	Deficits depend on the extent of collateral supply, and how quickly occlusion occurred. As many as 30-40% of carotid occlusions near the bifurcation are clinically silent.
MCA – main stem (M1)	Contralateral hemiplegia and hemisensory loss Contralateral hemianopsia Global aphasia (L)* or denial, neglect, and disturbed spatial perception perhaps with emotional ‘flatness’ (R)* Eye deviation to side of lesion acutely (gaze preference)
MCA – superior cortical division	Contralateral hemiparesis (face and arm > leg; and somewhat less often a cortical hemisensory loss; Broca’s aphasia (L)* or neglect and/or disturbed visual-spatial perception (R)* Eye deviation to side of lesion acutely (gaze preference)
MCA – inferior cortical division	Wernicke’s aphasia (L) or denial, neglect and/or disturbed visual-spatial perception (R)* Contralateral hemianopsia –mostly upper quadrants Contralateral somatosensory loss involving face, arm, hand possible; mild weakness of face/arm possible
MCA – lenticulostriate branch	“Pure motor” stroke often, but not necessarily, involving lower face, arm and leg equally but sparing sensation. Possibly dysarthria or ataxia as well.

*Assuming left hemisphere dominance for language

Extracranial Internal Carotid Artery

The mechanism of occlusion of the extracranial ICA is almost always formation of thrombus on an ulcerated atherosclerotic plaque located at or near the carotid bifurcation. Sometimes embolism from a cardiac source or carotid dissection is responsible, but this is less common. The clinical syndromes that result are variable – they can range from total infarction of the entire cortical and deep territories of the MCA and ACA (affecting most functions of one entire hemisphere) to a small cortical MCA territory infarction to no neurologic deficit whatsoever. **This incredible variability depends on what sources of collateral flow are available and how much blood the collaterals actually carried in the particular patient during the time immediately following ICA occlusion in the neck.**

Question: Can you think of several places where anastomotic flow might be established that could nourish carotid territory if the ICA were occluded slowly and progressively, allowing enough time for collaterals to increase their caliber and the amount of blood they carry?

Some possible answers:

- *Anastomoses via the circle of Willis:*
 - Enlarged posterior communicating artery connecting the vertebral-basilar to the carotid circulation
 - Enlarged anterior communicating artery connecting the carotid circulation on each side
- *External to internal carotid artery anastomoses, e.g. connections around the eye*
- *Cortical anastomoses between distal small cortical branches of MCA with ACA and PCA*

With all the variability in clinical presentation, you may be wondering how physicians come to suspect an ICA occlusion. The answer is often in the patient's past and present medical history. Clues include repeated transient ischemic attacks always in carotid territory, a carotid bruit or direct evidence of stenosis from angiography or ultrasound studies, or reversed blood flow in ophthalmic artery branches, (detected by transcranial doppler).

Question: If there is a functional anastomosis between the external and internal carotid artery enabling the external carotid to supply internal carotid territory, what direction would blood be flowing in the ophthalmic artery? (*Answer: inward*).

Strokes in Middle Cerebral Artery Territory

Infarctions in the distribution of the MCA are by far the most common strokes that are seen in clinical practice. Unlike the situation with the *extracranial* internal carotid artery, there are limited ways to establish anastomotic blood flow that can “rescue” ischemic tissue if the MCA or its branches are blocked. **Question:** Can you think of one possibility? *Answer: anastomoses between cortical branches in the border zones between MCA, ACA and PCA.*

Occlusion of the MCA stem is most often caused by embolism from a cardiac source or artery-to-artery embolism from the extracranial ICA. In a complete occlusion, blood flow is blocked both to the 10-15 deep penetrating lenticulostriate branches, which supply much of the internal capsule and basal ganglia, and to the superior and inferior cortical MCA branches, which supply most of the lateral cerebral cortex. As a result, much of the hemisphere is infarcted. Partial occlusions of the MCA stem can block blood flow to only lenticulostriate or only cortical branches.

After near-complete MCA stem occlusion, brain swelling may cause downward herniation of the medial temporal lobes leading to brainstem compression that kills the patient. Those who survive the initial period will develop contralateral hemiplegia affecting the lower face, arm and (to a lesser extent) leg accompanied by exaggerated reflexes and an extensor plantar response (damage to frontal lobe motor cortex and its projections). *However acutely there may be flaccid paralysis with absent reflexes.* These patients also have contralateral hemianesthesia produced by damage to the anterior parietal lobe somatosensory cortex, and a complete contralateral homonymous hemianopsia resulting from damage to the visual radiations as they travel from the lateral geniculate nucleus to the primary visual cortex.

In addition, damage to frontal, parietal, and temporal lobes near the lateral (sylvian) fissure in the language-dominant hemisphere (almost always the left one), produces **global aphasia**. Although conscious, these patients understand nothing that is said, and are unable to utter more than a few stereotyped sounds or words.

Damage to the posterior parietal and temporal lobes (most likely parts of the frontal lobes as well) in the non-language, right hemisphere produces a **severe defect in attention and/or visuospatial conceptualization**. These patients may neglect the left side of their own body and of their world. They may deny that their left limbs are paralyzed, or even deny that the left limbs belong to them. They may shave only the right side of their face, or draw only the right side of a symmetrical object such as a clock. They may have major problems in putting on clothes correctly, an activity that requires understanding 3-D visuospatial relationships. They often appear emotionally blunted, dull, inattentive, apathetic, or confused.

Occlusion of superior cortical branches in the left (language-dominant) hemisphere

Case Summary

At examination two months after his stroke, this patient had right hemiparesis, milder in the leg than in the arm and the lower part of his face. The deep tendon reflexes were exaggerated on the right and the plantar response was extensor– the sign of Babinski was present. Pinprick and two-point discrimination were mildly impaired on the right side of the face and arm, and joint position sense in his right fingers was much less accurate than in his left fingers. He could speak only a few words with great effort, and often answered questions using just a noun, leaving out grammatically correct connecting words like “the” or “of.” Writing was affected in the same way as speech. Additionally, he had difficulty repeating short phrases. However, he could carry out verbal commands, whether spoken or written, unless they were very long.

Expert Note: The patient’s right hemiparesis is produced by damage to either the left motor cortex or the corticobulbar and corticospinal axons that travel through the deep white matter of the hemisphere toward the internal capsule. The leg area of cortex should not be affected in an MCA branch occlusion since it is located on the medial aspect of the hemisphere (ACA territory). However the corticospinal axons for the leg must swing around the lateral ventricle as they travel to the internal capsule, and this puts them into superior branch MCA territory. Usually patients like this have much less weakness in the leg than in the arm and face. Explanations for the milder deficit in the leg often include the fact that leg motor cortex is still intact; however the exact cause remains unclear. Right-sided sensory loss reflects milder damage to the left somatosensory cortex for face and arm, which again is located on the lateral aspect of the left hemisphere.

This patient has Broca’s aphasia, which is an intellectual or cognitive deficit in assembling or expressing ideas with language, whether spoken or written. These same patients may also have difficulty enunciating words but that is because of weakness of muscles of facial expression in lower parts of the face and perhaps of the tongue (dysarthria). Much of the inferior frontal and parietal as well as superior temporal lobes and insular cortex near the lateral fissure are devoted to different aspects of language functions. A severe and lasting Broca’s aphasia like this patient has reflects damage to a large area centered in the left inferior frontal gyrus.

Occlusion of superior cortical branches in the right (non-dominant) hemisphere

Case Summary

At examination 3 months after her stroke, this patient had left hemiparesis, much milder in the leg than in the arm and the lower part of her face, with exaggerated reflexes. Two-point discrimination and pinprick were mildly impaired on the left side of the face and arm. When the left arm or right arm was tested alone, she reported when it is touched accurately; however when both the left and right arm were tested *simultaneously*, she reported touch only on the right arm. It is not safe for her to drive, because although she sees fairly well in both left and right visual fields, she doesn’t pay sufficient attention to things going on in the left side of space.

Expert Note: Like the patient with this lesion in the left language-dominant hemisphere, the patient described here also has a contralateral hemiplegia and mild sensory loss involving primarily face, hand, and arm. However instead of severe impairment of language, she has a different specific cognitive disorder involving neglect (lack of attention) to the left side of the space. In her case, which is quite mild, the problem causes her to ignore a stimulus delivered to the left side when stimuli are given bilaterally (extinction), although she responds to a stimulus given ONLY to the left side or ONLY to the right side..

We really don't understand the details, but clinical evidence suggests that the right hemisphere plays an important role in attending to the *entire* visuospatial world while the left hemisphere has a more limited role and attends only to the right. Thus damage to the right hemisphere would be expected to particularly affect attention to and conceptualization of *left* personal and general space. The anatomic basis is unclear, but there is evidence that spatial conceptualization involves systems distributed in the frontal as well as parietal and temporal lobes. Parts of these systems are therefore nourished by the superior cortical branches of MCA, although other critical components are in inferior MCA territory.

Additional Clinical Note: Immediately after their strokes, patients with superior cortical branch lesions in either the left or right hemispheres may have their eyes (turned toward the side on which their brain is injured). This severe gaze palsy usually lasts for only a few days, even when other motor deficits remain.

Question: Do you know of some part of the gaze mechanism that involves the frontal lobes?
Answer: *the frontal eye fields sometimes called the frontal lobe centers for contralateral gaze.* Each frontal eye field has a role in initiating voluntary eye movements to the opposite side. When it is damaged on one side the patient does not voluntarily move his eyes to the opposite side (and like the patient we've described may show a gaze preference to the side of the lesion).

Occlusion of inferior branches in the language-dominant hemisphere

Case Summary

The patient spoke fluently, and could carry on conversations confined to social pleasantries like responding to "How are you today?" However, as soon as the discussion went beyond these stock phrases to matters of substance, spontaneous speech became progressively more and more devoid of meaning. The patient seemed totally unaware that he was talking nonsense. Verbal or written instructions were not understood unless they were reinforced with non-verbal visual cues. Repetition was impaired. The patient showed no reaction to any visual stimulus (including visual threat) given in the upper right visual fields. No other deficits were noted on neurologic exam which included tests of eye movements, somatic sensation (so far as it could be tested), and movements of the face, arm, and leg.

Expert Note: The patient's fluent, melodic spoken language with little meaningful content, combined with an inability to comprehend spoken language, is characteristic of Wernicke's aphasia. His stroke, which affected the posterior part of the superior temporal gyrus and neighboring cortex, has disrupted the circuitry essential for comprehending sounds as being part of language and assigning them meaning. These patients do not understand what is being said to them, and their language is empty and meaningless, filled with sound-alike words, words used incorrectly, or totally made-up, meaningless words. Reading, writing, and speech are all similarly impaired.

Part of the visual radiations representing the contralateral superior quadrants loop forward into the temporal lobe, where they lie lateral to the ventricle before turning and running posterior to the medial occipital lobe (anatomists name this Meyer's loop). These fibers may therefore be at special risk from an MCA inferior cortical branch occlusion. Detailed visual field testing in a patient who cannot understand even simple directions is difficult. However where the patient does and doesn't see can be roughly determined by whether or not the patient responds to threatening gestures in each of the visual quadrants ('visual threat') by closing his or her eyes, making a face, or moving away from the stimulus.

The normal eye movements and normal motor and somatosensory components of the neurologic exam reinforce the idea that cortical regions supplied by the superior branch of MCA are intact.

Occlusion of inferior branches in the non-dominant hemisphere

Case Summary

When seen in clinic, this patient had no apparent motor deficit: there was no weakness and no gait abnormality. Although movements of the arms and hands were fluid and skillful, he had to labor for several minutes to button a single shirt button because he seemed not to understand how the button related to the buttonhole. His repeated efforts to put on a pair of work gloves were equally unsuccessful, and he ended up with the left glove on his right hand and 3 fingers where his thumb should go. Through all these efforts his face remained blank, with no indication of either concern or frustration. He spoke in a monotone. Pinprick, temperature and touch sensation were normal over both sides of the face, arm and leg when they were tested separately. However when tactile stimuli were presented simultaneously on the left and right, only the right-sided stimuli was recognized. He could not see objects on his left with either eye (visual field testing demonstrated an incomplete left homonymous hemianopsia).

Expert Note: This patient demonstrates several aspects of left-sided neglect. In addition, he seems to have lost an understanding of 3-D spatial concepts in general, as exemplified by his inability to button his shirt or put on gloves correctly (this is sometimes called dressing apraxia). The precise localization of his lesion is not known, but often the posterior parts of the parietal and temporal lobes are involved. His face and speech indicate little emotion, but it is difficult to know whether he is unconcerned by his deficit or is unable to express emotion through facial expressions or intonation as a result of the stroke. The incomplete homonymous hemianopsia is produced by damage to some of the fibers in the visual radiations that run through this region. The primary motor and somatosensory cortex, which tend to lie in the territory of superior MCA branches, were ultimately spared in this patient, although in the acute phase of his stroke he showed some facial weakness because of brain swelling that affected the functioning of the primary motor cortex.

Occlusion of a lenticulostriate branch

Case Summary

On his latest visit, this patient had severe paralysis of the lower part of the face, arm, and leg, all on the right. Tendon reflexes in the right arm and leg were exaggerated, and muscle tone was increased. The right plantar response was extensor (big toe up). He had marked dysarthria, but no other aspects of his neurologic exam were abnormal. Imaging studies at the time of his initial hospitalization showed left MCA stem stenosis, and an MRI confirmed a small infarct in MCA territory.

Expert Note: This patient had a pure motor stroke, without any impairment of sensation or any signs of cortical damage such as aphasia or neglect. The signs and symptoms can all be localized to the corticospinal and corticobulbar tracts on the left. Most commonly they are damaged either in the internal capsule or in the basal (ventral) pons. Imaging studies at the time of this patient's initial hospitalization showed severe narrowing of the left MCA stem near its origin. *MRI at 5 days showed a small infarct in the left internal capsule.*

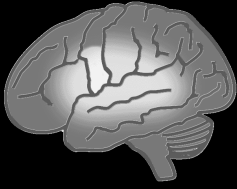The lenticulostriate branches of MCA are long, small diameter penetrating arteries that arise directly from the MCA stem and supply most of the internal capsule and basal ganglia. Imaging suggests that this patient may have experienced blockage of a lenticulostriate artery at its origin from the MCA stem. This produced a small infarct (or lacune) in the posterior limb of the left internal capsule, damaging the corticobulbar and corticospinal tracts on their way from the motor cortex to the brainstem and spinal cord. In another patient, a similar small infarct could be produced by collapse of a lenticulostriate artery occluding the lumen, likely caused by the lipohyalinotic wall thickening that was initiated by uncontrolled hypertension.

This small-vessel stroke produced major deficits because of its location, as in this patient who has significant motor deficits (a pure motor stroke). In other cases, a small-vessel (or lacunar) stroke may produce no abnormalities detectable on neurologic exam. The old real estate broker's adage, 'location, location, location,' is particularly applicable in this situation.

A pure motor stroke (with no abnormal sensory findings) can also be produced by damage in the base (ventral region) of the pons. Module 5 (Vertebral-basilar Territory) describes such a case.

Ischemia in the ACA-MCA Cortical Border Zone

When blood flow in the carotid artery is suddenly reduced secondary to severe global hypotension or arterial dissection, structures in the cortical border zone that lies between distal branches of ACA and MCA can be at risk of ischemia. The ACA-MCA border zone is located in superior parts of the frontal lobe, which includes primary motor cortex concerned with the proximal limb girdle of the arm or leg, or both. However the exact position of the border zone varies between individuals, depending on factors such as whether there is long-standing carotid stenosis. One patient with border zone infarction suffered primarily paralysis of the contralateral hip sparing the rest of the leg. Another patient had a paralyzed shoulder and was initially worked up for a brachial plexus injury until other neurologic deficits made it clear that his problem was inside the CNS. The MCA-PCA border zone is also at risk if there is hypotension and poor distal perfusion.



Module 5. Ischemia in Vertebral-basilar Territory **Introduction and Key Clinical Examples**

Objectives for Module 5

Knowledge

- List 4 common symptoms that patients might experience during TIAs produced by ischemia in vertebral-basilar territory.
- List 5 important signs and symptoms that may be seen after infarction of the dorsolateral region of the rostral medulla, and relate each to damage to a specific neuroanatomic structure.
- Describe the problem with memory that is commonly produced by bilateral PCA occlusion.

Clinical Applications and Reasoning

- Explain how bilateral signs can be produced by occlusion of a single artery in the brainstem.
- Explain why crossed motor or sensory deficits are a signature of brainstem ischemia (e.g., the combination of ipsilateral cranial nerve signs but contralateral long tract signs).
- Compare and contrast the patterns of clinical findings seen after bilateral occlusion of all cortical PCA branches vs. occlusion of only those branches supplying the primary visual cortex.
- Explain the term ‘macular sparing,’ and suggest one explanation for why it sometimes occurs following PCA branch occlusion.

Clinical Applications to Patient Education

- Develop points that you could use in explaining to a patient how they might personally experience a TIA produced by temporary occlusion of vertebral-basilar branches.

Transient Ischemic Attacks involving vertebral-basilar branches

TIAs in the vertebral-basilar territory can produce a number of different symptoms, reflecting the many functions of the brainstem. Because the basilar artery is a single midline artery whose branches supply both sides of the brainstem, TIAs can produce bilateral as well as unilateral motor or sensory findings. In addition, because the basilar artery bifurcates to form both posterior cerebral arteries, temporary occlusion at this upper bifurcation can also produce ischemia in the thalamus or medial temporal and occipital lobes bilaterally.

The most common symptoms reported in vertebral-basilar TIAs include vertigo (this is a false sense of movement that may be described by a patient as ‘dizziness’), nausea, and unsteady gait. Their high frequency most likely reflects the number of brainstem structures related to the vestibular system and cerebellum. However, episodes of ‘dizziness’ or nausea are not uniquely associated with TIAs (nor is every TIA producing ‘dizziness’ caused by blockage of vertebral-basilar branches). Accurate diagnosis and localization of vertebral-basilar territory TIAs usually depends on other symptoms in addition to ‘dizziness’ such as cranial nerve abnormalities.

Transient vertigo and dysarthria – a brainstem TIA

Case Summary

The patient suddenly developed vertigo (“the room was spinning”) while getting up out of his chair, lost his balance, became nauseated and vomited on the living room floor. He was able to call out to for help, but when his wife came running in from the next room she noticed immediately that his speech was slurred and hard to understand. She called 911. EMTs arrived about 20 minutes later, and transported him to the nearest hospital. He began to improve in the ambulance. By the time they reached the ED he was speaking clearly again and could sit up. An electrocardiogram revealed atrial fibrillation. He was observed closely for the next 18 hours, and there were no further events. His neurologic exam showed no lasting deficits. The patient’s atrial fibrillation was addressed by electrical cardioversion and antiarrhythmic medications, and anticoagulation therapy was initiated.

Expert Note: This patient had a TIA, most likely produced by a cardiac embolus that initially lodged in one vertebral artery and then broke up. The TIA lasted approximately an hour before the deficits began to clear. Like many patients with ischemia in vertebral-basilar territory, he experienced problems related to malfunction of the vestibular system. Vertigo can be caused by peripheral (labyrinthine or CNVIII) as well as CNS (brainstem) dysfunction, but the combination of vertigo *and* dysarthria often suggests a central lesion (brainstem or possibly cerebellar involvement).

Question: Why does atrial fibrillation increase the risk of TIA or stroke? (*Answer: ineffective contraction of the atrial muscle increases the likelihood that thrombus will form in the atrium – this is a potential source of emboli*)

Some symptoms that are commonly produced by vertebral-basilar TIAs include:

- Unilateral or bilateral** weakness, clumsiness or paralysis
- Limb ataxia, staggering or veering when attempting walking [cerebellar signs]
- Vertigo or ‘dizziness’ [especially in combination with other brainstem/cerebellar symptoms]
- Unilateral or bilateral** numbness or paresthesias (burning, tingling etc.) or loss of sensation
- Dysarthria
- Nystagmus (repetitive involuntary eye movements) or diplopia (double vision)
- Visual field loss or blindness (suggesting unilateral or bilateral damage to the visual cortex in the occipital lobe, which is supplied by the posterior cerebral arteries)

** Since branches of the basilar artery supplies both sides of the brainstem, its occlusion can affect motor or sensory long tracts bilaterally.

Common Strokes involving the vertebral-basilar circulation

Blocked Artery or Branch	PATTERNS OF POSSIBLE DEFICITS
One vertebral artery in the rostral medulla; in some cases, blockage of the PICA branch	Loss of pain sensation on the ipsilateral side of face, but contralateral trunk and limbs; hoarseness, impaired swallowing, and ipsilateral vocal cord paralysis; ipsilateral ataxia and Horner's syndrome; vertigo, nausea, and vomiting (complete Wallenberg's syndrome).
Penetrating paramedian basilar branch in the ventral pons	Contralateral hemiplegia; involvement of face depends on whether rostral or caudal pons (pure motor stroke); cerebellar ataxia if pontine nuclei / connections involved
Basilar occlusion affecting the ventral region of the <u>rostral</u> pons bilaterally	Bilateral complete paralysis rendering patient motionless and mute although alert, aware, and capable of perceiving sensory stimuli. Vertical eye movements and blink spared if midbrain is not involved (locked-in syndrome)
Penetrating PCA branch supplying the thalamus	Many possibilities. May produce loss of all somatic sensations in contralateral face and body; initially hemianesthesia --later may develop a thalamic pain syndrome with painful dysesthesias in affected (anesthetic) regions
Unilateral cortical branches of PCA supplying the occipital lobe	Contralateral homonymous hemianopsia with or without macular sparing depending on the extent and location of the lesion
Bilateral occlusion of all PCA cortical branches distal to the thalamic penetrators	Inability to form memories of new facts and events; cortical blindness, which may be accompanied in the acute stage by the patient denying any problem seeing

Occlusion of one vertebral artery (or PICA) supplying the lateral rostral medulla
<p style="text-align: center;">Case Summary</p> <p>On recent examination, this patient had a hoarse voice, and often coughed when he attempted to swallow. His uvula deviated to the left when saying "aah", and the gag reflex was absent on the right. He had nystagmus that became particularly noticeable when he looked to the left. The patient's gait was unsteady, and the finger-to-nose and heel-to-shin tests demonstrated dysmetria of arm and leg movements on the right. He had lost pain and temperature sensation on the <i>right</i> side of the face, but on the <i>left</i> limbs and trunk. His right pupil was smaller than the left (right miosis) but was reactive to light, and his right lid drooped slightly (mild right ptosis).</p>

Expert Note: The patient has infarcted the dorsolateral region of the rostral medulla on the right side. This is the most common ischemic brainstem stroke. The combination of signs and symptoms that he shows is often referred to as Wallenberg's syndrome. It used to be thought

that this syndrome was only produced by posterior inferior cerebellar artery occlusion; however more recent studies suggest that in many of these patients it is thrombosis (blockage) of one vertebral artery itself that is responsible.

The hoarse voice, difficulty in swallowing, leftward deviation of the uvula, and absent right gag reflex all suggest damage to axons of CNIX or CNX (or nucleus ambiguus) on the right. The nystagmus (together with the vertigo, severe nausea and vomiting that patients like this often experience) is produced by damage to the vestibular nuclei or vestibular connections with the cerebellum. Difficulty coordinating right limb movements suggests involvement of the inferior cerebellar peduncle or perhaps part of the cerebellum itself, both on the right side.

The loss of pain and temperature sensation on the *right side of the face* is likely caused by interruption of the descending trigeminal tract, which is uncrossed. The spinothalamic tract, which runs close to the descending tract crossed in the spinal cord, so it carries information about pain and temperature in the *left (opposite) side of the body*.

Clinical Reminder: Brainstem lesions typically produce cranial nerve signs ipsilateral to the lesion but long tract sensory deficits in the trunk and limbs contralateral to the lesion because the major somatosensory pathways for the body (spinothalamic tract and medial lemniscus) cross at or below the caudal medulla.

When a Horner's syndrome (ptosis, miosis, and less commonly facial anhidrosis) is produced by a lateral medullary lesion, the cause is interruption of descending fibers (from hypothalamus or reticular formation) traveling in lateral parts of the reticular formation that will synapse on the preganglionic sympathetic neurons of the intermediolateral column in the high thoracic spinal cord.

Clinical Pearl: In Horner's syndrome, the lesion is always on the same side as the symptoms.

Occlusion of a perforating branch of the basilar artery in the pons

Case Summary

On examination, this patient had a pure motor hemiplegia that involved the arm and leg on one side of the body. Reflexes in the paralyzed arm and leg were exaggerated, and the plantar response was extensor. There were no accompanying abnormal sensory or visual findings, and no cognitive deficits such as aphasia or neglect.

Expert Note: This patient has a small-vessel ischemic stroke in the base (ventral) of the pons, caused by occlusion of a small paramedian penetrating branch of the basilar artery. The damage interrupts the corticospinal tract, which is located in the base of the pons, producing contralateral upper motor neuron paralysis of the arm and leg with exaggerated reflexes and an extensor plantar response. There is no cortical or thalamic damage so no cognitive or visual deficits are present, and the somatosensory system is also spared since these pathways run in the more dorsal parts of the pons. Recall that a small-vessel stroke in the internal capsule caused by occlusion of a lenticulostriate artery can also produce a pure motor stroke but there is usually weakness of the lower face as well as arm and leg. In pontine lesions, the face may be involved, or may be spared, as it was in this patient, because the corticobulbar fibers have separated from the corticospinal tract, and are located much farther dorsal. By contrast, the corticobulbar and corticospinal tracts run close to each other in the internal capsule, and both would likely be affected by a relatively small lesion.

If the pontine lesion is less severe, producing a milder motor problem (a hemiparesis instead of hemiplegia), there may also be ataxia or 'clumsiness' of the weakened limbs. Ataxia would not be seen if there is complete limb paralysis -- to detect the presence of cerebellar ataxia (incoordination of voluntary limb movements) it is essential that the patient be able to move the limb! The ataxia, a problem with cerebellar function, presumably reflects damage to corticopontine fibers, the pontine nuclei (griseum pontis) or their axons (pontocerebellar fibers) projecting to the contralateral cerebellum via the middle cerebellar peduncle.

Occlusion of the basilar artery in the rostral pons

Case Summary

When seen on work rounds, this patient showed no spontaneous movement of her face, tongue, neck, trunk or limbs. She was intubated to protect her airway. She was believed to be totally unresponsive until a medical student discovered that she could move her eyes vertically on command. Using a code of up for "yes" and down for "no," the student demonstrated that the patient knew what hospital she was in, how long she had been there, her diagnosis, the names of many of her doctors and nurses, and remembered many day-to-day events of her hospital stay. Although she had no other voluntary movements except vertical eye movements and the ability to lift her eyelids, she had preserved cognition, somatic sensation, vision, hearing, taste.

Expert Note: In this patient, occlusion of the basilar artery just distal to the superior cerebellar arteries has produced infarction of the base of the rostral pons *bilaterally*. Interruption of the corticobulbar and corticospinal tracts caused the complete paralysis of all voluntary movements except certain eye movements. The patient's neurologic deficit is referred to as the *locked-in* state.

Voluntary *horizontal* eye movements are impossible because they require intact projections from the frontal lobe (via the superior colliculi) to structures in the caudal pons. *Vertical* eye movements are spared since the entire pathway for voluntary vertical eye movements is contained in the midbrain (location of brainstem vertical gaze centers and the oculomotor and trochlear nuclei and nerves) and forebrain, all of which are intact because they are located rostral to the patient's lesion.

The reticular formation and other structures located in the midbrain continue to get adequate blood flow, accounting for the patient's being awake, alert, aware of herself and her surroundings, and capable of perceiving sensory stimuli. One possible explanation is that the size and arrangement of arteries in her Circle of Willis allowed enough blood to flow *from* the internal carotid arteries through the posterior communicating and *into* the posterior cerebral arteries to supply these areas.

Occlusion of a penetrating PCA branch to the thalamus

Case Summary

When seen in clinic, this patient could not feel any *gentle* stimulus over his entire right side including face, neck, body, and limbs. However, he was extremely apprehensive about sensory testing since any sufficiently intense right-sided stimulus (even shaking hands) produced an overwhelming wave of unbearable, surrealistic pain that lasted for several minutes. Cold stimulation was particularly effective in producing such pain, and he was terrified to even touch a glass containing cold water. Left-sided sensations were normal.

Expert Note: This patient has a small infarct in the posterior part of his left thalamus that involves the somatosensory nuclei (their names are VPL ventral posterolateral and VPM ventral posteromedial) where the spinal cord and brainstem somatosensory pathways terminate. Therefore all modalities of somatic sensation are impaired on his right side. His distressing over-response to cold stimuli is an example of *neuropathic pain* that reflects abnormal over-activity somewhere in the system for processing painful stimuli secondary to thalamic injury. Details of the mechanism of the *thalamic pain syndrome* are not known.

Spontaneous pain syndromes can result from lesions in other regions of the CNS as well, and by themselves do not localize the lesion to the thalamus. In this patient other neighboring parts of the thalamus and its fiber connections were apparently spared. The various thalamic nuclei provide critical inputs to specific regions of cortex, and lacunar strokes involving the thalamus may produce other deficits ranging from movement disorders to aphasias.

Occlusion of PCA cortical branches to the left occipital lobe

Case Summary

This patient had no other neurologic deficit except a complete right homonymous hemianopsia, which means that when his eyes were stationary he could not see objects on his right side with either eye. He was very aware of his visual loss, and compensated by moving his eyes in order to bring objects in his blind field into view. By this means, he was able to see objects on both sides of pictures and read across a whole page of written text without hesitation. Pupillary light reflexes were normal.

Expert Note: In this patient the medial aspect of the *left* occipital lobe is infarcted. The patient realizes that he can't see objects on his right, and moves his eyes to bring them into view. He does not neglect objects even if they are in his blind regions. By contrast, patients with a larger lesion in the *right* occipital lobe that involves neighboring parts of the right parietal and temporal lobes may lose the 'concept' of the left side of themselves or of their world.

Recall that central (macular) parts of the visual fields are mapped onto the more posterior parts of the medial occipital lobe. In different patients the macular region may be entirely in PCA territory, or it may be in the border zone between MCA and PCA cortical branches and therefore largely spared in a PCA infarct. In this patient the left macular region was apparently supplied only by the PCA, so it was entirely infarcted. Because PCA cortical branches do not supply the retina, the optic tract, or the midbrain, the pupillary light reflexes are normal.

Temporary blockage of most cortical branches of PCA bilaterally

Case Summary

This patient had heart valve surgery 6 years ago, and has a mechanical mitral valve. One day at work he abruptly collapsed, unconscious. By the time EMTs brought him to the hospital, he had regained consciousness. In the emergency department he was found to have "tunnel vision," i.e., he was blind except in the central parts of his visual fields. In addition, he could not remember new events or new facts for more than about 2-3 minutes and was therefore unable to learn any doctor's name or even to appreciate that he was in a hospital. By the following afternoon, the blindness and inability to memorize new information began to gradually clear up. Yesterday on rounds, his one remaining neurologic problem was total amnesia for a period of about 4 weeks prior to this incident and for the 24 hours that followed its onset.

Expert Note: It is likely that a piece of thrombus on the surface of the mechanical heart valve broke off. The resulting embolus probably passed readily through the large diameter basilar artery, but was arrested by the narrowing at its upper bifurcation. The patient's collapse and temporary unconsciousness were caused by the sudden interruption of input from rostral parts of the brainstem reticular formation to the cerebral cortex. Function was restored because the embolus obstructing the upper basilar bifurcation quickly broke up. However several of its pieces apparently entered both PCAs and briefly blocked cortical branches *bilaterally* before completely disintegrating. The nearly complete loss of vision reflects malfunction of much of the primary visual cortex produced by ischemia. Although these regions temporarily ceased to function correctly, their neurons did not die since the patient later regained normal visual fields. The patient's central vision was spared, suggesting that in his brain the macular representation must lie in a cortical region that never became ischemic.

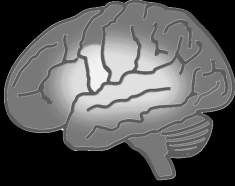Cortical branches of PCA to the inferior medial temporal lobes also supply much of the hippocampus/entorhinal area and associated white matter. These structures are important in declarative memory, as this patient illustrates. Recall that the patient was able to converse with his physicians throughout this episode, so he remembered how to use language. Furthermore, he was able to remember new people and factual information very briefly. However he was incapable of retaining or retrieving this new information after more than about three minutes elapsed. The patient soon recovered normal memory function, but experienced retrograde amnesia, a “hole in his memory,” for events that occurred in the 4 weeks immediately prior to his stroke.

In this patient, brief ischemia involving the hippocampus/entorhinal area and its connections permanently disrupted the processing (sometimes referred to as “consolidation”) of memories involving events just prior to the stroke. This suggests that conversion of a block of temporally-related memories from some transient to a more permanent form occurs slowly, over a period of weeks. In this patient the amnesia is the result of bilateral ischemic damage involving the medial temporal lobe.

What about the spinal cord – isn’t it also nourished by vertebral branches?

Vascular disease in the spinal cord is uncommon. Unlike arteries in the brain, spinal arteries are not particularly susceptible to atherosclerosis or embolization. However, infarction of the spinal cord can occur after surgery that involves aortic repair, or in cases where a dissecting aneurysm of the aorta blocks radicular vessels. The collateral arteries that supply the spinal cord vary somewhat in size, and a catastrophic drop in blood pressure may result in ischemia in vulnerable segments (those at mid-thoracic levels are especially at risk). This is the spinal cord equivalent of a border zone infarct in the cerebral hemispheres.

When the *anterior* spinal artery is blocked, there is bilateral paralysis and a deficit in pain sensation below the level of the lesion. However discriminative touch, joint/limb position and vibratory sense are all spared since the posterior columns and neighboring white matter are supplied by the *posterior* spinal arteries.



Module 6. Preventing and Treating Ischemic Stroke: An Introduction to Therapy

Objectives for Module 6

Knowledge

- List 5 recommendations that you could make to help patients reduce their risk of having a first stroke (primary prevention), and reflect on barriers that may limit their ability to follow them
- For a patient who has experienced a recent TIA or ischemic stroke, list 3 appropriate strategies for secondary prevention. What additional measures should be considered when there is (1) an identified source of cardiac emboli or (2) carotid stenosis that's likely related

Clinical Applications and Reasoning

- List immediate diagnostic studies for evaluation of a patient with suspected acute ischemic stroke, and why they are critical for early therapeutic intervention
- Describe time factors and several additional considerations that determine patient eligibility for therapies involving intravenous alteplase (fibrinolytic) and/or mechanical thrombectomy
- Describe additional healthcare measures aimed at improving the clinical outcome of a patient diagnosed with an acute stroke

Clinical Applications to Patient Education

- Develop a plan for discussing the key warning signs of stroke with a 70-year-old patient who has at least 3 major stroke risk factors
- Plan your response to a patient who states: "there's no rush to get help if you think you're having a stroke---you're as good as gone anyway..."

Risk Factor Control to Prevent a First Stroke (Primary Prevention)

RISK FACTOR	Recommendations
Current Cigarette Smoking	Counseling to help patient stop smoking; smoking cessation programs; nicotine replacement
Lack of Regular Physical Activity	As medically appropriate, exercise program providing at least 150 min. of moderate (75 min vigorous) activity per week; strengthening at least 2 days per week.
Excessive Alcohol Consumption	Counseling to reduce alcohol consumption to an average of 1 drink/day (female) or 2 drinks/day (male) and to stop binge drinking; cessation programs if needed
Obesity (BMI ≥ 30)	Diet and exercise aimed at reducing weight to achieve a body mass index (BMI) < 25 (25-29 is considered 'overweight'; ≥ 30 is 'obese')

RISK FACTOR	Therapeutic Goal	Recommendations
High Blood Pressure	Decrease build-up of atherosclerotic plaque; reduce direct damage to walls of small arteries and arterioles	Lifestyle modifications and antihypertensive medications reducing blood pressure to <130/80 mm Hg (New guideline)
Acute Myocardial Infarction especially if anterior or septal region of heart wall is damaged	Prevent thrombus from forming on ischemic endocardium	Oral anticoagulants or antiplatelet agents
Any condition, including MI, that reduces motion of the heart wall	Prevent thrombus from forming in ventricle	Oral anticoagulants (preferred) or antiplatelet agents
Atrial Fibrillation	Restore normal rhythm Prevent clot formation in left atrium	Cardioversion, ablation, and/or antiarrhythmic drug therapy Oral anticoagulants (preferred) or antiplatelet agents
Elevated Fasting Glucose Diabetes Mellitus	Decrease rate of atherosclerosis, and its secondary consequences such as hypertension	Diet, oral hypoglycemics, or insulin to reduce or normalize blood glucose levels if possible
High Total Cholesterol (and other lipids)	Reduce or prevent atherosclerotic plaque formation	Diet limiting saturated fats, increased physical activity, often a statin or related agents
Carotid Artery Stenosis (asymptomatic)	Prevent thrombus formation on existing atherosclerotic plaque	Antiplatelet agents
	Improve blood flow by increasing diameter of lumen	Endarterectomy or stenting; possible plaque reduction by diet or statins

Structural and Social Determinants of Health such as education, income, zip code poverty, health insurance, availability of healthcare, environmental factors, stress can limit a patient’s ability to address stroke risk factors. They likely contribute to reported disparities in stroke incidence in different populations.

Important Areas of Patient Education about Stroke

- Realizing that addressing modifiable risk factors can significantly reduce overall stroke risk
- Recognizing the common signs and symptoms of stroke (F.A.S.T.)
- Knowing to call 9-1-1 immediately if warning signs occur (use of EMS generally preferred)
- Understanding that new therapies which may limit or even reverse deficits must be administered in the first hours following on stroke onset – every second matters
- Seeking immediate medical help for stroke warning signs even if they last for only a few minutes
- Understanding that if a stroke or TIA does occur, aggressive follow-up health care can help prevent future strokes

▪ Treatment of Ischemic Stroke

“My husband and I were having breakfast together. I noticed that he was trying to reach for his coffee mug with his right hand, but now he could barely move his arm. His banana and bagel were falling out of the right side of his mouth. He wasn’t talking, just mumbling some sort of gibberish. However he seemed to understand that I was telling him. I knew something was wrong and called 9-1-1. We live just up the street from the hospital, and EMS got him to the ED in about 25 minutes.”

NOTE: Use of 911/EMS is recommended as this provides an opportunity for stroke screening, blood glucose determination (finger stick), pre-notification of ED, and potentially rapid transport to closest facility that can capably administer thrombolytic and endovascular therapy if there is suspicion of stroke.

***A patient with the abrupt onset of neurologic symptoms arrives in the ED
What should happen next?***

▪ Therapy 0-6 Hours After Symptom Onset

The INITIAL goals in this early phase are to provide medical support for the patient, establish a clinical diagnosis of stroke, and determine whether the stroke is ischemic or hemorrhagic. The patient’s airway, breathing, and circulation are constantly reassessed. The first question to be answered is whether this is a stroke or a stroke mimic (e.g. seizure, migraine, hyperglycemia, hypoglycemia). To establish the clinical diagnosis, physicians consider the patient’s history and physical examination, and whether the neurologic symptoms and signs conform to a vascular pattern. A blood glucose test is done, and a non-contrast head CT scan is obtained as quickly as possible to determine the presence or absence of hemorrhage. (The goal is imaging within 20 min of arrival in ED). Recall that a CT study performed in the first hours can rule out hemorrhage but may not visualize *ischemic regions*, even ones that later will produce large infarcts. CTA of intracranial and extracranial vessels may be simultaneously performed, but this should not delay administration of thrombolytic therapy to eligible patients. Various blood tests and an ECG are requested, but only the assessment of blood glucose (to rule out diagnosis of metabolic encephalopathy) must precede initiation of IV tPA.

Once hemorrhage is excluded the administration of intravenous (IV) tissue plasminogen activator (tPA) may be considered. This thrombolytic drug opens blocked arteries by activating an enzyme that breaks up strands of fibrin that hold together a blood clot (either an embolus or thrombus.) **Eligible patients should be treated as quickly as possible. Federal guidelines recommend treatment within 3 hours of the time of observed symptom onset; however treatment of selected patients between 3 and 4.5 hours can be beneficial and is supported.**

“My husband was examined and had his CT scan right away. The neurologist recommended IV tPA therapy and explained its dangers but also its potential benefits to both of us. She told me getting to the hospital so quickly after his symptoms started improved the chances of success. They started the drug about 1.5 hours after his problem started. As I watched, I could see the strength coming back in his hand. Six months later things have improved a lot, but aren’t the same. For instance, he has to ‘work’ at saying things clearly, and sometimes he struggles to find the word he wants to say.”

MORE ABOUT IV tPA: Over the past ten years, there have been a number of clinical studies examining outcomes of IV tPA therapy for acute ischemic stroke. While details vary, they collectively demonstrate that *the sooner the treatment is initiated, the better the long-term outcome.* On average, treatment within 90 minutes of symptom onset or last known well is associated with the most favorable outcomes, with favorable outcomes decreasing with time but still demonstrating benefit at 3 to 4.5 hours for selected patients.

Although other tests will certainly have been ordered, the only results that are essential before the time-sensitive decision about IV tPA therapy is made are the non-contrast head CT scan and blood glucose level (finger stick). The list of exclusion criteria for this therapy includes a number of conditions that would indicate an increased risk of bleeding within the brain or at other sites, for instance uncontrollable hypertension, stroke in prior 3 months, bleeding disorders, recent surgery.

MECHANICAL THROMBECTOMY Recent clinical trials have demonstrated that **mechanical thrombectomy using stent-retriever devices is highly beneficial in eligible patients with causative occlusions of the internal carotid or proximal middle cerebral artery (large-vessel occlusions) up to 6 hours after stroke onset.** In selected patients mechanical thrombectomy up to as many as 24 hours after the last known normal time may provide functional benefit. Although there is less clinical experience, patients with occlusion of the vertebral, basilar or posterior cerebral arteries may also be treated with mechanical thrombectomy.

As with IV tPA, treatment with mechanical thrombectomy should be initiated as quickly as possible. Patient age, NIH Stroke Scale score, or prior receipt of IV tPA does not rule out thrombectomy **It is recommended that patients eligible for IV tPA should receive it, even if mechanical thrombectomy is being considered.**

A dreaded complication of both IV tPA and mechanical thrombectomy can be severe or even fatal intraparenchymal brain hemorrhage, so the risks and the potential benefits should be discussed with the patient and/or family, and informed consent obtained prior to administration if possible.

Currently, IV tPA and/or mechanical thrombectomy will benefit only those stroke patients who arrive quickly enough to be eligible, and who also meet additional criteria. Furthermore, to take advantage of mechanical thrombectomy the patient must be at a healthcare facility with rapid access to cerebral angiography, neurointerventional radiologists, and a specialized care team. At this time the outcomes of both these therapies are variable. While a number of patients appear to benefit significantly, others may receive limited benefit, and a small number experience hemorrhagic complications that worsen their deficits or lead to death. Hopefully, future developments in thrombolytic, endovascular and neuroprotective treatments may provide more powerful or universally helpful alternatives.

More About Testing That Is Part Of The Acute Stroke Work-Up

During the first hours after an ischemic stroke, an important goal is to figure out the cause and the location of the blockage. To establish whether the occlusion involves a large extracranial or intracranial artery, Doppler ultrasound or CT angiography can supplement the history and physical exam. As mentioned previously, some centers now combine CT angiography (and CT perfusion imaging) with the initial non-contrast CT scan to expedite the stroke workup, because CTA images the both the extra and intracranial arterial system to localize any significant stenosis or occlusion causing the stroke. An electrocardiogram may demonstrate presence of intramural (within left atrium or ventricle) thrombus, right to left shunt, regional or global myocardial wall weakness that may predispose to thrombus formation.

During this very early phase, MRI is commonly used only in major stroke centers. In that setting, diffusion-weighted imaging can be used to detect very early infarcts. MR perfusion studies can be performed using gadolinium contrast. Brain regions showing poor perfusion but no abnormality on diffusion are considered equivalent to the *ischemic penumbra* -- brain regions that may be at risk of ischemia/infarction but are potentially salvageable if revascularized. Although it is an imperfect approach, the ability to image the ischemic penumbra may be helpful in selecting patients who might benefit from mechanical thrombectomy.

▪ **Therapy Beyond 6 Hours**

If a patient presents more than six hours after symptom onset, physicians ask many of the same diagnostic questions: Is this a stroke? What caused it? What can I do to prevent another stroke?

IV tPA therapy is not usually an option at this time, because of the increased risk that arteries in the ischemic region of brain will hemorrhage if blood flow is restored. However, mechanical thrombectomy may still be considered, especially in the setting of a clinical trial, if the patient meets criteria and therapy can be initiated with little further delay.

Some of the additional medical issues for physicians in this later phase include:

- Prevention of direct complications of stroke, such as brain swelling and potential herniations
- Control of excessive hypertension, hyperglycemia, dehydration, and fever
- Prevention of secondary complications resulting from the patient's relative immobility, such as deep venous thrombosis, aspiration pneumonia (caused by stroke-related inability to swallow), pressure sores, and contractures (flexion or distortion of joints due to weakness and spasticity).

At this time, physicians provide supportive medical care, prevent and treat any acute complications, attempt to determine what caused arterial obstruction, and assess the extent of vascular disease and the need for medical or surgical treatment. Aspirin is often given within 24-48 hours after stroke onset.

Secondary Prevention After a First TIA or Ischemic Stroke

Patients with TIAs (mini-strokes) should be evaluated very promptly. The risk of stroke after a TIA is currently about 7% in the first 90 days, and a number of the strokes occur in the next 1-2 days. The number of strokes occurring soon after TIAs has decreased, thanks in part to more timely and effective secondary prevention measures.

A major goal of evaluating patients who have had a TIA or acute ischemic stroke is to determine the *specific etiology (cause)* of the cerebral ischemia, so that the most appropriate therapy can be quickly initiated to prevent recurrence.

Medical and surgical therapies, as well as lifestyle modifications, can help prevent a second stroke. Strategies for secondary prevention commonly include (1) blood pressure control (however blood pressure control in the acute setting requires caution and expertise), (2) statins, and (3) antiplatelet therapy (except in patients who require anticoagulant therapy). Depending on what the diagnostic evaluation indicates about the most likely cause of the TIA or first stroke, additional medical, endovascular and/or surgical therapies may also be recommended.

(1) High blood pressure is the most important modifiable risk factor for both primary and secondary prevention of stroke. A number of clinical trials indicate benefits of blood pressure reduction in stroke prevention, regardless of the initial blood pressure levels. However the most effective blood pressure target is debated. Whether any particular class of antihypertensive agents conveys specific benefit in stroke reduction also remains somewhat controversial.

(2) Statins are effective in both primary and secondary stroke prevention. Whether their benefit extends beyond LDL-C level reduction is unclear, although many suspect that this is the case.

(3) Antiplatelet therapy (platelet aggregation inhibitors) is recommended for secondary stroke prevention unless anticoagulation is indicated (see below). These drugs prevent platelets from sticking to each other, and therefore limit the growth of *platelet-rich, relatively fibrin-poor thrombus* on the surface of a damaged atherosclerotic plaque whether in extracranial or intracranial cerebral arteries.

Patients with *carotid stenosis* have a reduced incidence of stroke when they are placed on platelet aggregation inhibitors. Stenosis indicates the presence of atherosclerotic plaque that could become thrombogenic. Presumably antiplatelet drugs reduce the chance of thrombus formation leading to complete vascular occlusion as well as embolization. Antiplatelet therapy is also generally recommended in patients with a patent foramen ovale who have had a stroke or TIA.

The following antiplatelet agents are all acceptable first-line options in secondary stroke prevention:

- **Aspirin** prevents the aggregation of platelets through its irreversible action on an enzyme of prostaglandin metabolism (prostaglandin G/H synthase). *Its effects are rapid.* This is first line (and lowest cost) therapy for patients with TIA and ischemic stroke.
- **Clopidogrel** (Plavix ®) also irreversibly prevents platelet aggregation, but does so by action on the cyclic-AMP pathway. *It takes up to 5 days to become maximally effective.* [Note that Aspirin and Clopidogrel are often given together]
- **Aspirin-Extended Release Dipyridamole** (Aggrenox ®) is a combination of aspirin with another platelet aggregation inhibitor (dipyridamole, a phosphodiesterase inhibitor).

ANTICOAGULATION THERAPY is often recommended if a patient has atrial fibrillation (or other cardiogenic sources of thromboemboli) The traditional mainstay of therapy has been **warfarin (Coumadin ®)**. This is an anticoagulant that opposes the formation of fibrin by inhibiting the synthesis of vitamin K dependent clotting factors. It therefore is particularly effective in preventing the extension of large, well-formed cardiac thrombi, which tend to contain a *major component of fibrin with entrapped red blood cells as well as platelets.*

Three of the major conditions leading to thrombus formation in the heart are:

- **Atrial fibrillation** in which asynchronous contraction of the muscle of the left atrium results in failure to empty the chamber and stagnation of blood leading to thrombus formation within the atrium. *At least 15% of ischemic strokes are caused by atrial fibrillation.*
- **Valve abnormalities or prosthetic heart valves**, which are thrombogenic.
- **Abnormally reduced motion of the heart wall**, which may occur after a myocardial infarction or other damage to the heart muscle that decreases its ability to empty the ventricles with each cardiac cycle. Blood becomes stagnant, and thrombus tends to form. Recall that emboli from the left ventricle can travel anywhere in the body, including the brain; however emboli from the right ventricle travel to the lungs unless there is an abnormal right-left shunt in the heart.

In each of these conditions, controlled clinical trials have shown that short-term or long-term treatment with **warfarin** reduces the risk of cardioembolic stroke. **Patients on warfarin therapy must be regularly monitored by tests of prothrombin time (a specific coagulation test).** Additionally, warfarin can have dangerous side effects and interactions. Because of the risk of hemorrhagic side effects, warfarin is contraindicated in people with bleeding disorders or a history of gastrointestinal bleeding, in people who are at risk for falls (unsteady walking, very elderly), in people who are unreliable at taking their medications. These individuals are often given aspirin therapy as an alternative. Aspirin has considerably less efficacy for prevention of cardioembolic stroke than warfarin, because aspirin alters only platelet function and does not affect the humoral clotting system.

Both initiation and management of warfarin therapy are often difficult for physician and patient alike. For this reason, there is a lot of interest in new alternative oral anticoagulant strategies that do not require monitoring: **dabigatran** (a direct thrombin inhibitor) and two direct factor Xa inhibitors (**apixaban** and **ribaroxaban**). Clinical data are still limited, but initial results have shown that all three reduce stroke risk in patients with atrial fibrillation similar to warfarin. These or other new agents may replace warfarin for many patients, but at present there remain some concerns about a possibly higher risk of systemic bleeding.

SURGICAL OR ENDOVASCULAR THERAPY to improve cerebral blood flow may be recommended if the patient's extracranial internal carotid artery is narrowed by atherosclerosis,

- **Carotid endarterectomy** involves opening the artery and scooping out the accumulated atherosclerotic material, along with any thrombus that has formed. This procedure has demonstrated benefits that must be weighed against its risks, including the chance of a heart attack or stroke that may be fatal. Carotid endarterectomy has been shown to be effective in reducing risk of initial or recurrent stroke *if there is symptomatic high-grade carotid stenosis (70-99%), and if total surgical complication risk for the patient is <6%*. Carotid endarterectomy provides a modest benefit in symptomatic patients with moderate stenosis.
- **Endovascular therapy** Angioplasty with or without stenting is a relatively newer procedure for improving flow in the extracranial carotid artery and in some intracranial vessels that are not accessible surgically. In angioplasty, a catheter is used to position a balloon inside the artery. The balloon is then inflated to enlarge the arterial lumen and restore more normal blood flow. In stenting, the artery is held open by a permanent support after the angioplasty is done. One recently completed randomized trial compared carotid endarterectomy with stenting and found no difference in the primary end point of stroke, MI, or death. However in individuals over age 70, carotid endarterectomy was associated with fewer strokes -- and a somewhat enhanced quality of life.

Surgery in the vertebral-basilar system is relatively less common.

How are things different if the stroke is Hemorrhagic?

Many hemorrhagic strokes initially produce severe or unusual headache and nausea or vomiting, with or without loss of consciousness. Although this presentation increases the clinical suspicion of a hemorrhage, a non-contrast head CT scan is key to confirming the diagnosis. The CT scan differentiates hemorrhagic from ischemic stroke in the first 24 hours. It also provides additional critical information about the size and location of hemorrhage, and may sometimes reveal structural abnormalities like aneurysms, arteriovenous malformations, or tumor causing the hemorrhage.

In the case of **intraparenchymal hemorrhage**, there is no clinically-proven, specific medical or surgical therapy, and general medical management is similar to that for patients with ischemic infarction except for relatively more aggressive treatment of hypertension. In addition, any clotting disorders must be corrected. Brain swelling or mass effect of the hemorrhage blocking the flow of CSF, or compressing the brainstem or other structures may require surgical intervention. Evacuation of hematomas above the tentorium does not appear to improve the outcome. However evacuation of large cerebellar hemorrhages to relieve pressure on the brainstem can provide significant benefit.

At present, the prognosis for patients with large or medium size clots is usually grave. However patients with smaller hemorrhages can experience a slow but remarkable return of function. Apparently a small hemorrhage can sometimes push aside brain tissue and disable it temporarily without destroying it. As the clot is slowly reabsorbed, neural function returns.

Prevention: Although there is no conclusive evidence, most stroke experts believe that the treatment of hypertension is probably the most effective means of preventing the majority of intraparenchymal hemorrhages. Reducing excessive alcohol consumption including binge drinking and the use of drugs like cocaine and amphetamines is also important. In addition, careful control of anticoagulation levels in patients receiving warfarin and careful selection of patients for fibrinolytic therapy (whether for acute MI or stroke) should decrease the rate of intraparenchymal hemorrhage.

In the case of nontraumatic **subarachnoid hemorrhage** due to a ruptured saccular aneurysm, an early CT scan will usually detect blood locally or diffusely in the subarachnoid spaces or extending into the ventricular system. In a number of cases, subarachnoid hemorrhage is rapidly fatal in a matter of a few hours. The hemorrhage increases intracranial pressure to a level that approaches arterial pressure, causing a sudden drop in cerebral blood flow and leading to loss of consciousness, coma, and death. If the patient survives the initial period, there is continued danger of rebleeding. Cerebral vasospasm (constriction of cerebral arteries in response to presence of blood in the subarachnoid space), may diminish blood flow to parts of the brain causing an ischemic stroke.

Currently most aneurysms are treated by inserting tiny thrombogenic metal coils into the aneurysm using an endovascular approach via an angiography catheter. Surgery to occlude the neck of a balloon-shaped aneurysm with a metallic clip is now a far less common approach. Repair is usually undertaken as soon as possible because untreated, ruptured aneurysms will often rebleed.

Prevention: Most aneurysms reflect developmental abnormalities. However their rupture may be associated with smoking or hypertension. If an unruptured aneurysm is detected, it is often recommended that it be repaired although the decision to repair should be individualized depending on the size and location of aneurysm. However, routine screening of at-risk individuals (positive family history or disorders associated with high risk of aneurysms) is not currently recommended.

Stroke Rehabilitation

Rehabilitation of stroke patients begins in the acute care hospital. Patients with mild strokes whose condition is stabilized may leave the hospital for home in less than a week, and may receive outpatient or home physical and occupational therapy. Other patients may be sent to a rehabilitation facility where more extensive and comprehensive care involving physicians, nursing, and therapists is available.

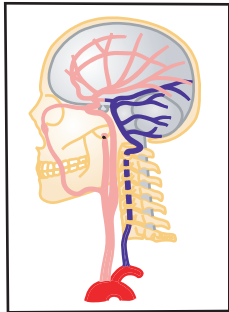
Recovery from an ischemic stroke may begin in a few days although it may be delayed and slow in some patients. Early recovery most likely results from restoration of function in uninfarcted brain. Physical therapy may include constraint-induced movement therapy in patients with arm weakness (immobilizing their *unaffected* side to force the use of the affected side, and requiring use of the affected arm repetitively and intensely for several weeks). This novel therapeutic approach can sometimes improve the functional use of the affected arm to carry out activities of daily living. Over time, apparently other brain areas can take on some of the functions previously carried out by the infarcted regions (neural plasticity). Patients may also “work around” any disabilities by figuring out different ways of doing things.

In a hemorrhagic stroke, brain tissue surrounding the hemorrhage is displaced and compressed but not necessarily infarcted. Therefore in a patient who survives a hemorrhagic stroke, reabsorption of the hematoma is often associated with a return of function in the adjacent tissue – and a remarkable decrease in the patient’s deficits.

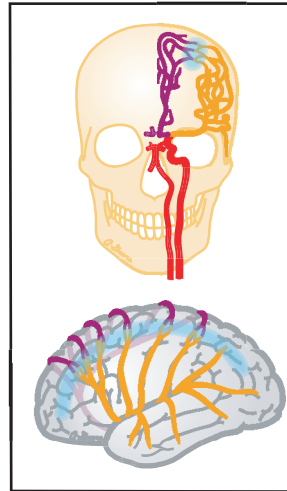
Structural as well as Social Determinants affect access to stroke care and the quality of that care. Currently opportunities for evidence-based stroke prevention, treatments such as intravenous thrombolysis and mechanical thrombectomy, and rehabilitation are not equitably distributed to individuals and populations in the United States.

StrokeSTOP Reference Drawings

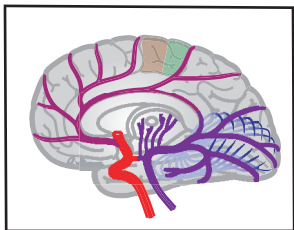
(by Anne B. Greene, MA, CMI)



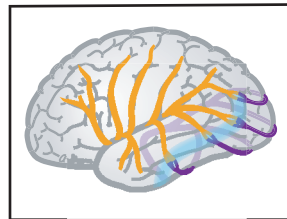
1. CAROTID-VERTEBRAL
Vessel origins and distributions



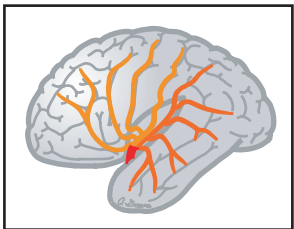
7. ACA-MCA ANTERIOR & LATERAL
Border zones



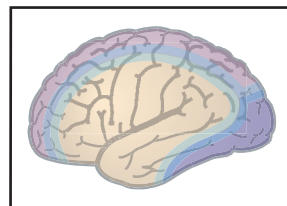
2. MEDIAL BRAIN
ACA
PCA
Functional areas



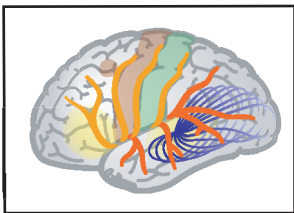
8. MCA-PCA LATERAL
Border zones



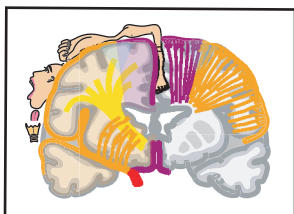
3. LATERAL BRAIN OPENED
MCA - superior and inferior branches



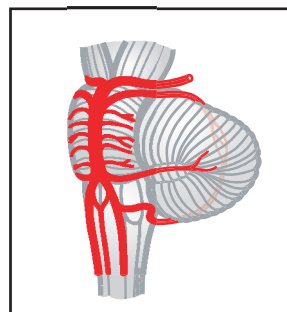
9. FOREBRAIN TERRITORY MAPS
Lateral
Medial
Horizontal
Superior
Inferior



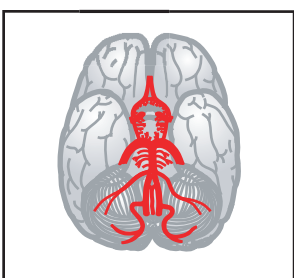4. LATERAL BRAIN
MCA
Functional areas



5. CORONAL BRAIN
ACA
MCA

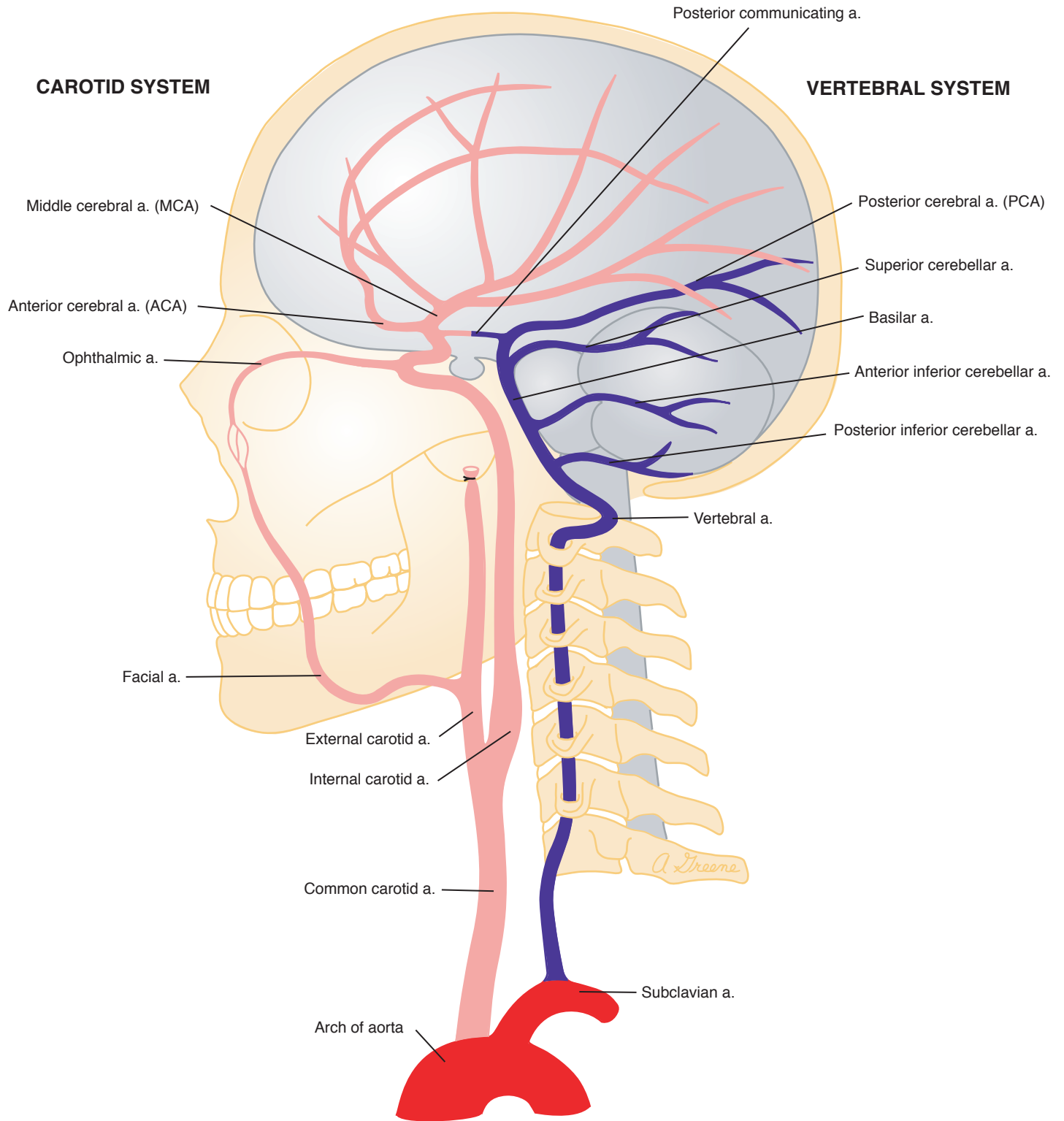


10. BRAINSTEM SYNDROMES
Midbrain
Mid-pons
Caudal pons
Rostral medulla



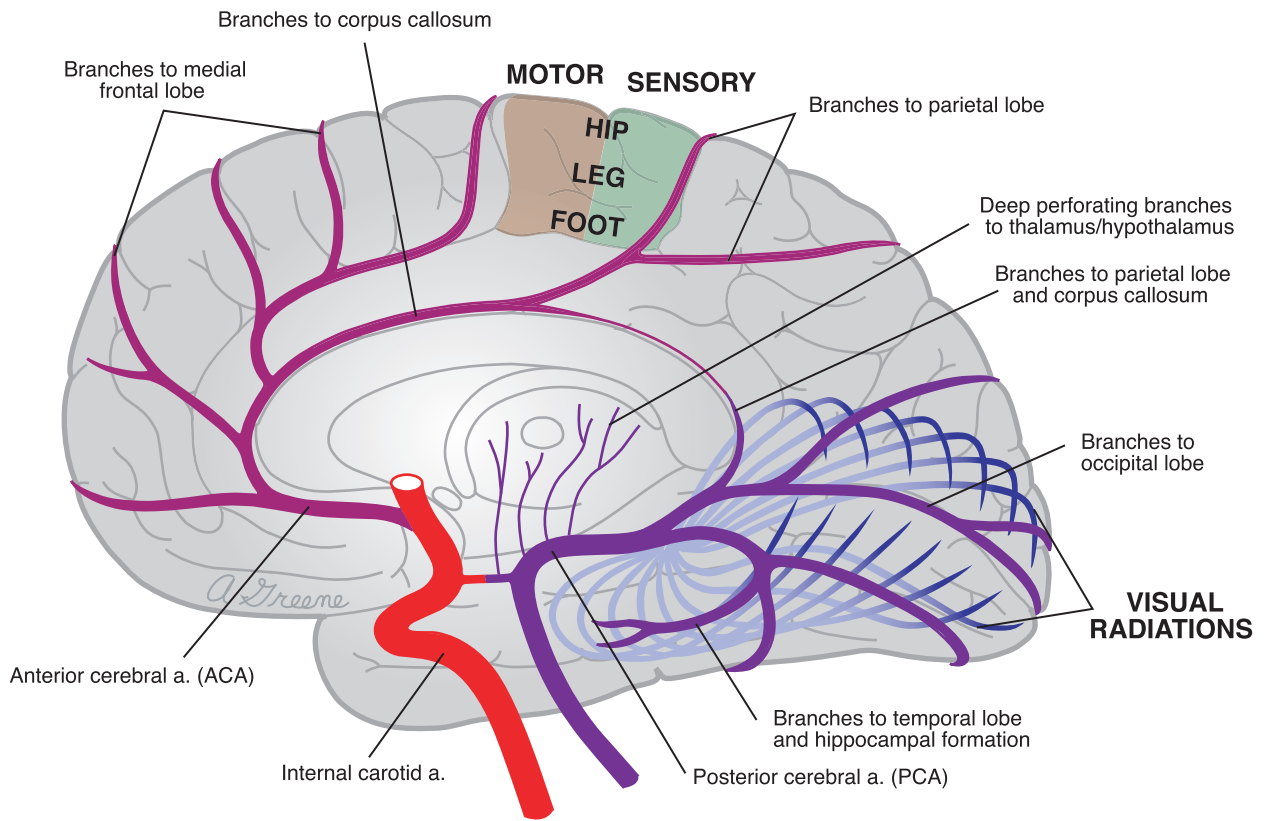
6. BASE OF BRAIN
Carotid system
Vertebral-basilar system

1. CAROTID-VERTEBRAL



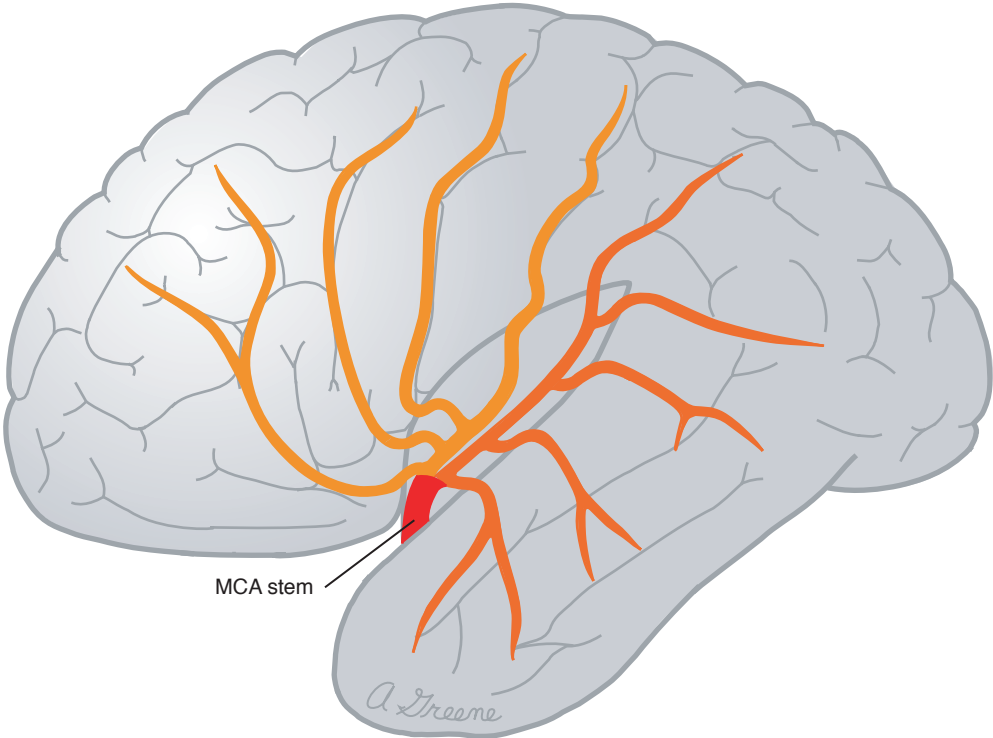
StrokeSTOP Reference Drawings by Anne B. Greene
 © 2000 University of Massachusetts Medical School
 and the American Stroke Association



2. MEDIAL BRAIN



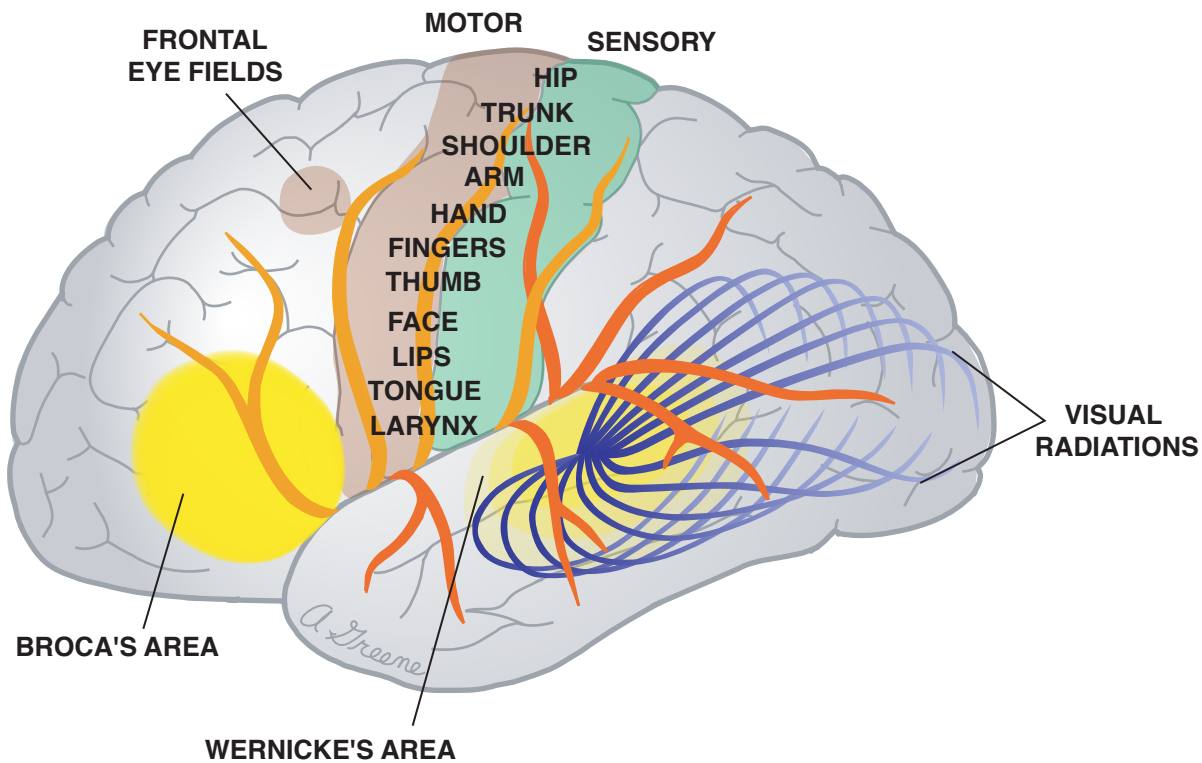
KEY	
	Anterior cerebral a. (ACA)
	Posterior cerebral a. (PCA)



3. LATERAL BRAIN OPENED



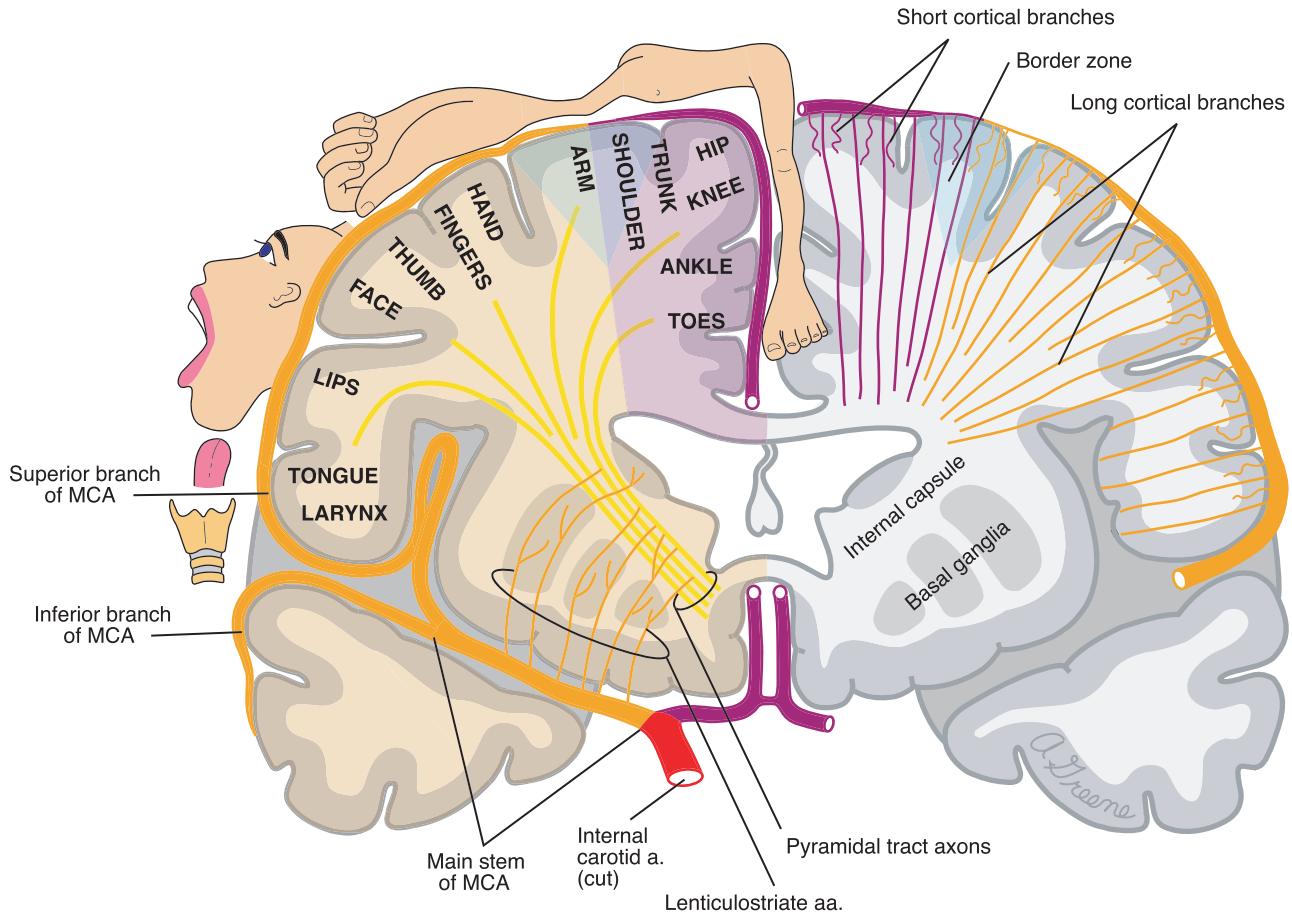
KEY	
	Superior branches of middle cerebral a. (MCA)
	Inferior branches of middle cerebral a. (MCA)






4. LATERAL BRAIN



KEY	
	Superior branches of middle cerebral a. (MCA)
	Inferior branches of middle cerebral a. (MCA)

5. CORONAL BRAIN

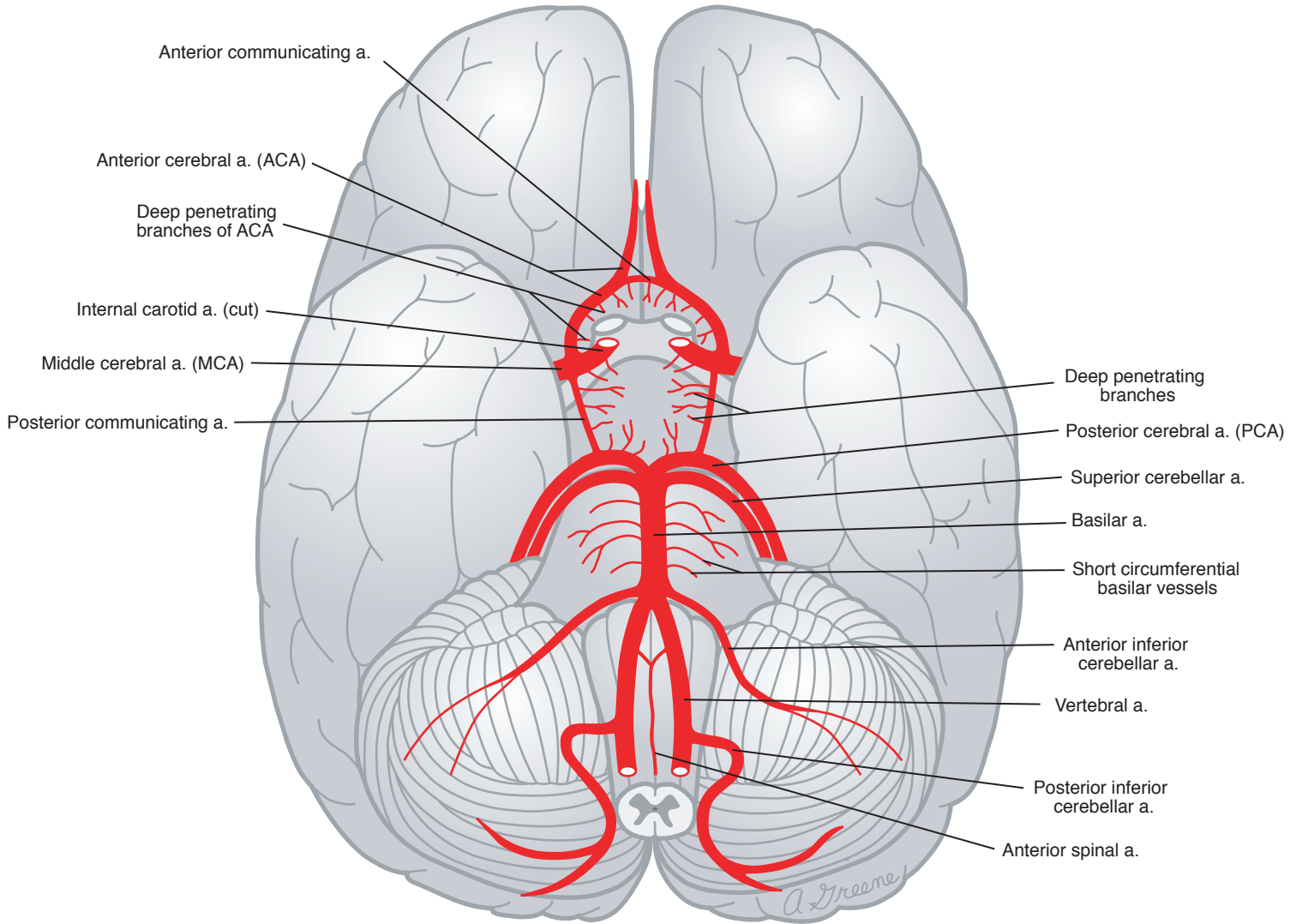


KEY	
	Anterior cerebral a. (ACA)
	Middle cerebral a. (MCA)
	ACA territory
	MCA territory
	Border zone

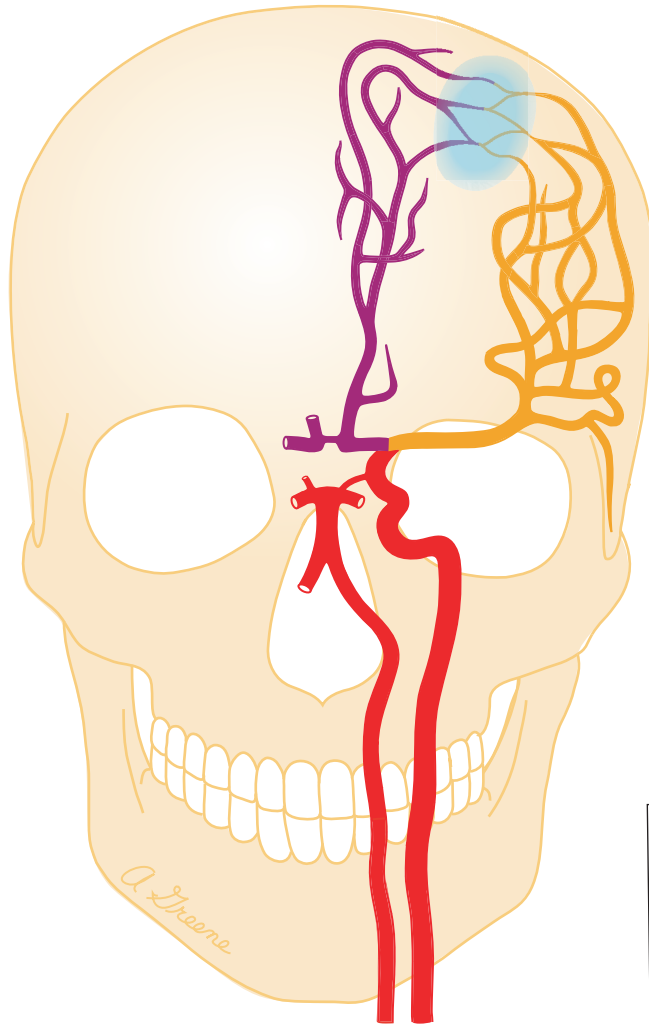
6. BASE OF BRAIN

CAROTID SYSTEM




VERTEBRAL-BASILAR SYSTEM

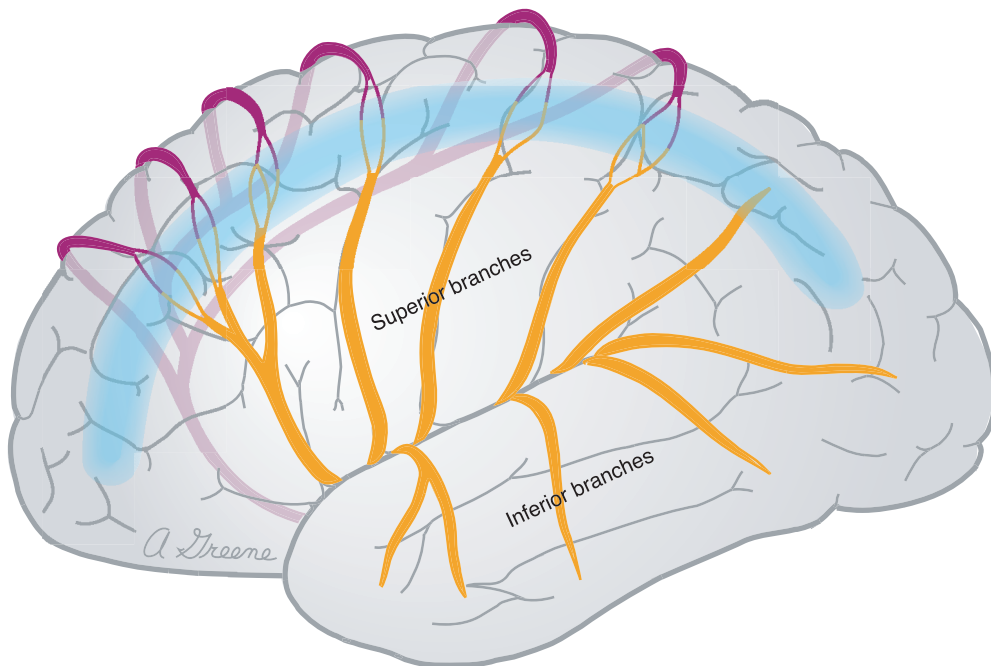


7. ACA-MCA



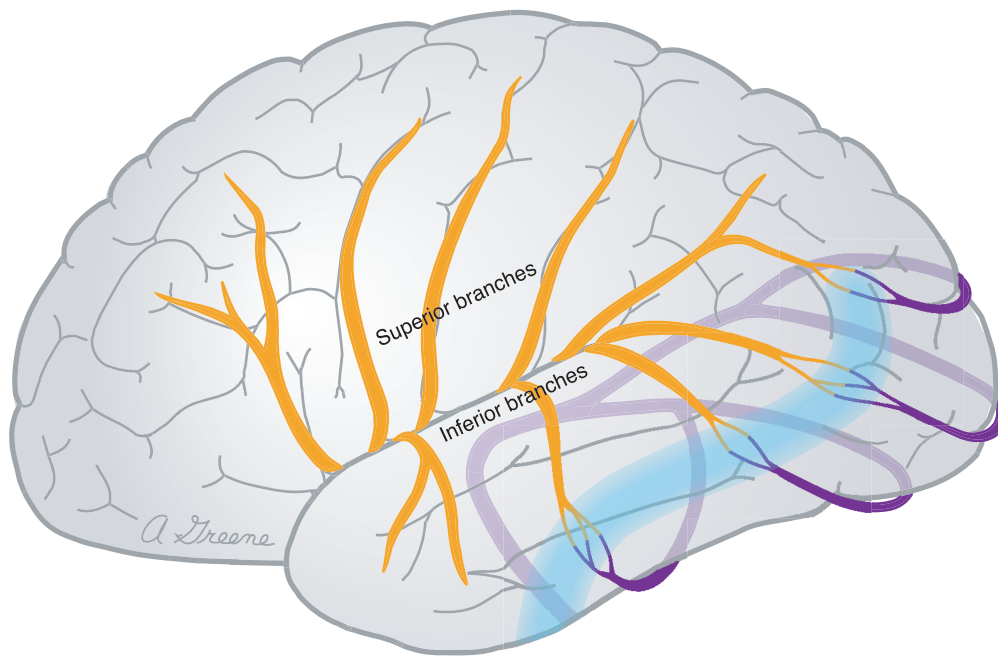
ANTERIOR




KEY	
	Anterior cerebral a. (ACA)
	Middle cerebral a. (MCA)
	Border zone



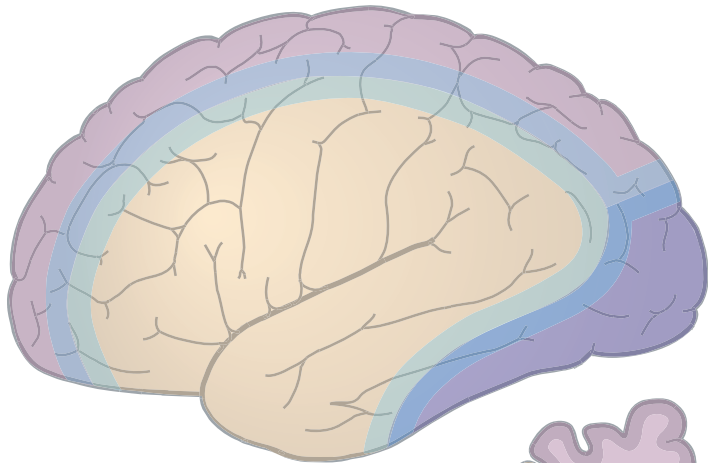
LATERAL

8. MCA-PCA LATERAL

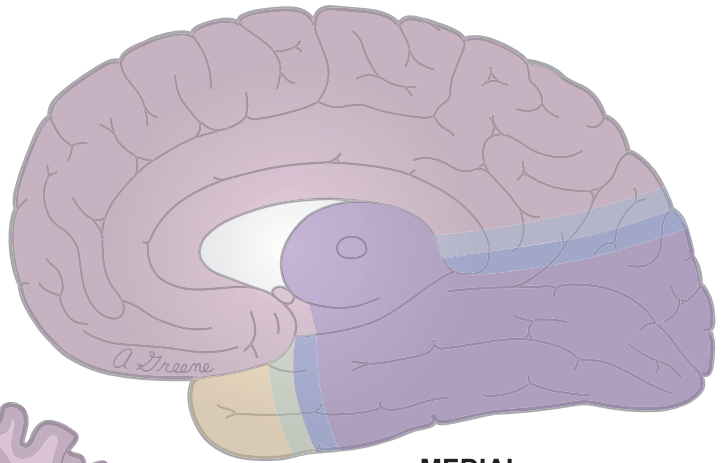


KEY	
	Middle cerebral a. (MCA)
	Posterior cerebral a. (PCA)
	Border zone

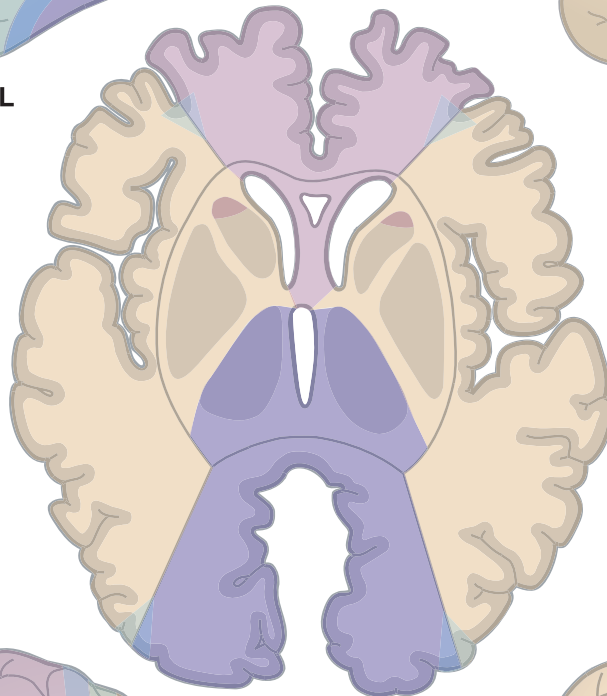
9. FOREBRAIN TERRITORY MAPS







LATERAL

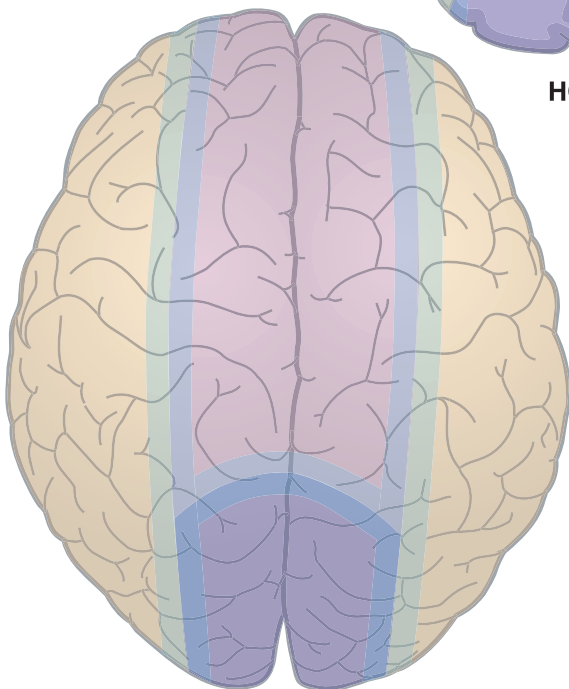


MEDIAL

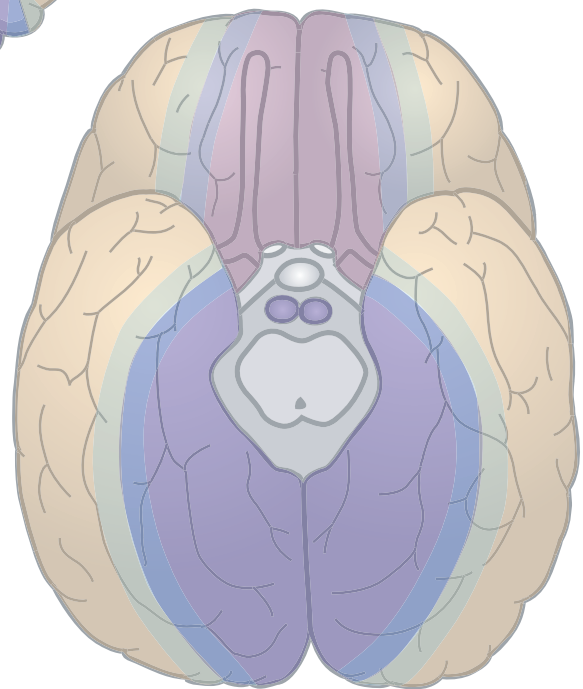


HORIZONTAL

KEY	
	Anterior cerebral a. (ACA)
	Middle cerebral a. (MCA)
	Posterior cerebral a. (PCA)
	Border zone



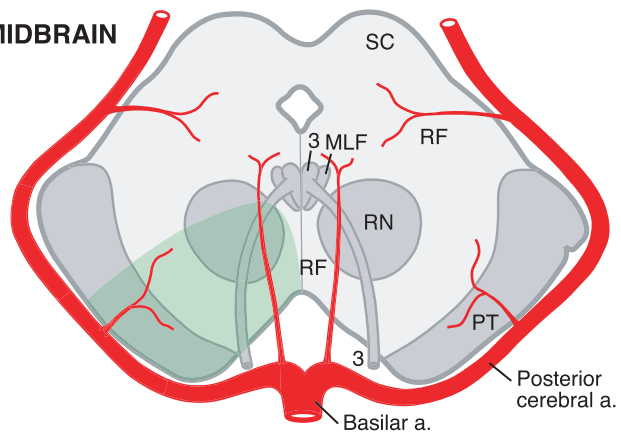
SUPERIOR



INFERIOR

10. BRAINSTEM SYNDROMES

MIDBRAIN



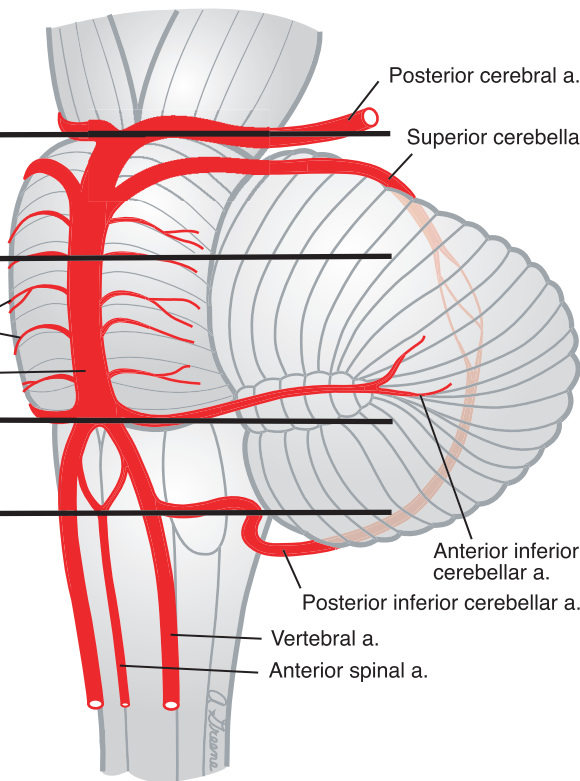
MIDBRAIN

MID-PONS

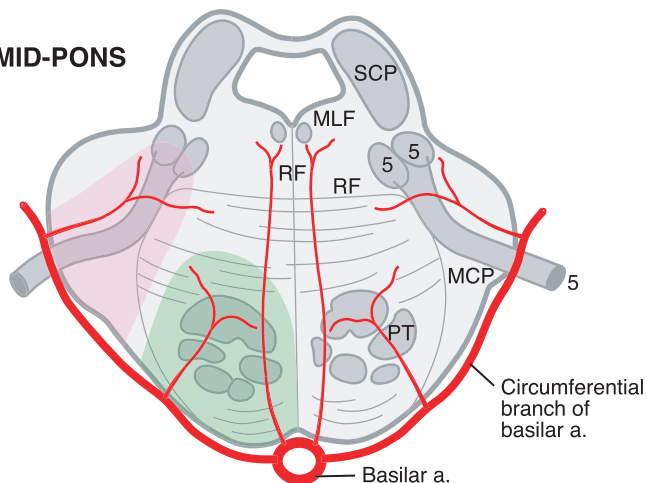
Short circumferential branches of basilar a.

CAUDAL PONS

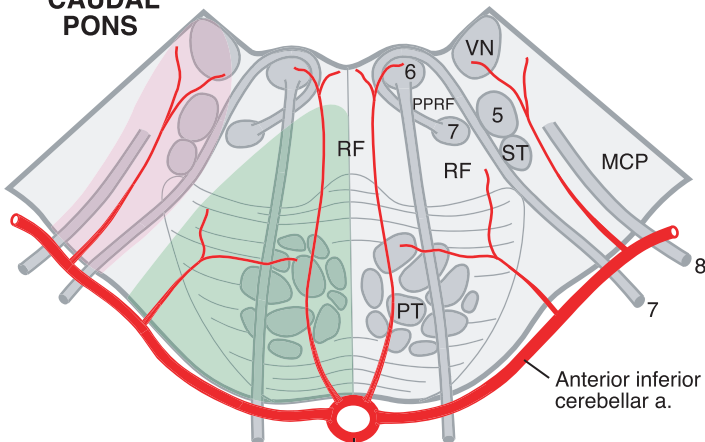
ROSTRAL MEDULLA



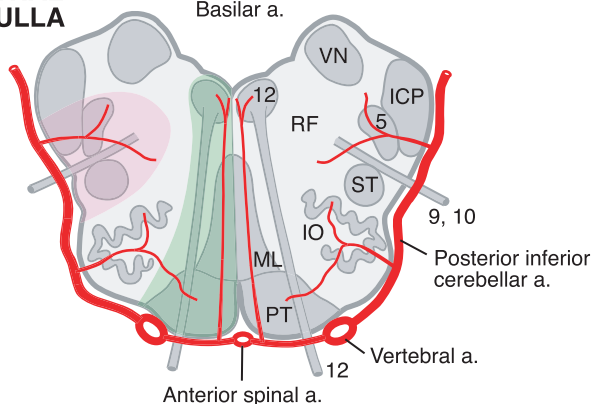
MID-PONS



CAUDAL PONS



ROSTRAL MEDULLA



KEY

- IO Inferior olivary complex
- ML Medial lemniscus
- MLF Medial longitudinal fasciculus
- PPRF Paramedian pontine reticular formation
- PT Pyramidal tract
- RF Reticular formation
- RN Red nucleus
- SC Superior colliculus
- ST Spinothalamic tract
- VN Vestibular nuclei

- ICP Inferior cerebellar peduncle
- MCP Middle cerebellar peduncle
- SCP Superior cerebellar peduncle

3-12 refer to cranial nerves or their nuclei

- Medial syndrome
- Lateral syndrome